

Current Knowledge and Perspectives for the Use of Platelet-Rich Plasma (PRP) and Platelet-Rich Fibrin (PRF) in Oral and Maxillofacial Surgery Part 1: Periodontal and Dentoalveolar Surgery

Marco Del Corso^{1,2}, Alain Vervelle¹, Alain Simonpieri¹, Ryo Jimbo^{3,4}, Francesco Inchingolo⁵, Gilberto Sammartino² and David M. Dohan Ehrenfest^{1,6,*}

¹The LoB5 Foundation for Research, Paris, France; ²Department of Odontostomatological and Maxillofacial Sciences, University Federico II of Naples, Italy; ³Department of Biomaterials, Institute for Clinical Sciences, The Sahlgrenska Academy at University of Gothenburg, Sweden; ⁴Department of Prosthodontics, Faculty of Odontology, Malmö University, Malmö, Sweden; ⁵Department of Dental Sciences and Surgery, University of Bari, Italy; ⁶LoB5 unit, Chonnam National University School of Dentistry, Gwangju, South Korea

Abstract: Platelet concentrates for surgical use are innovative tools of regenerative medicine, and were widely tested in oral and maxillofacial surgery. Unfortunately, the literature on the topic is contradictory and the published data are difficult to sort and interpret. In periodontology and dentoalveolar surgery, the literature is particularly dense about the use of the various forms of Platelet-Rich Plasma (PRP) - Pure Platelet-Rich Plasma (P-PRP) or Leukocyte- and Platelet-Rich Plasma (L-PRP) - but still limited about Platelet-Rich Fibrin (PRF) subfamilies. In this first article, we describe and discuss the current published knowledge about the use of PRP and PRF during tooth avulsion or extraction, mucogingival surgery, Guided Tissue Regeneration (GTR) or bone filling of periodontal intrabony defects, and regeneration of alveolar ridges using Guided Bone Regeneration (GBR), in a comprehensive way and in order to avoid the traps of a confusing literature and to highlight the underlying universal mechanisms of these products. Finally, we particularly insist on the perspectives in this field, through the description and illustration of the systematic use of L-PRF (Leukocyte- and Platelet-Rich Fibrin) clots and membranes during tooth avulsion, cyst exeresis or the treatment of gingival recessions by root coverage. The use of L-PRF also allowed to define new therapeutic principles: NTR (Natural Tissue Regeneration) for the treatment of periodontal intrabony lesions and Natural Bone Regeneration (NBR) for the reconstruction of the alveolar ridges. In periodontology, this field of research will soon find his golden age by the development of user-friendly platelet concentrate procedures, and the definition of new efficient concepts and clinical protocols.

Keywords: Blood platelet, fibrin, growth factors, leukocytes, oral surgery, periodontics, platelet-rich fibrin (PRF), platelet-rich plasma (PRP), regenerative medicine, tissue engineering.

1. FROM FIBRIN GLUES TO PLATELET CONCENTRATES: AN ORAL AND MAXILLOFACIAL STORY

The development of platelet concentrates (PC) for topical use is deeply associated with oral and maxillofacial surgery since the beginning of the craze for these technologies [1-3]. Nowadays, more than the half of the publications on these products are related to oro-facial sciences. The history of these techniques probably explains this over-representation of maxillofacial applications with these products.

Historically, PC are the natural evolution of the fibrin sealants developed more than 40 years ago [4], when clinicians started to manipulate the numerous actors of the coagulation process in order to use them in clinical situations [5]. The first fibrin glues were mainly fibrinogen concentrates, tested in plastic surgery for skin healing [6]. Skin is logically the first tissue where fibrin bandages and glues were tested easily. Some authors however tried to add platelets to the seautologous preparations in order to increase the strength of the fibrin glue, and developed first applications in ophthal

mological surgery [7, 8] and even neurosurgery [9]. The fibrin glues were only used as sealant, with quite good results [10]. However, good clinical results are often not enough to launch the development of a technique ; economic considerations are also at stake. The autologous fibrin glues (with or without platelets) were too complicated and time-consuming to prepare [11], and these techniques were therefore never widely developed. Regularly, new researches and protocols for autologous fibrin glues were proposed, but marketed fibrin glues (with lyophilized fibrinogen concentrate from blood bank) became quickly the main techniques in daily practice, even if very expensive [6]. Even during the long « fibrin glue » era, the applications of these products were over-represented in oral and maxillofacial surgery [5, 11].

The main explanation of this situation is probably related to the intrinsic nature of oral and maxillofacial surgery: this field requires relatively small volumes of products, but the need for healing stimulator is very important. The anatomy of the face is one of the most complex in the organism, with a light bone architecture pneumatized with many cavities, and an intertwining of organs, tissue and functions superposed in a relatively small area: the 5 senses are directly or indirectly dependent on the anatomy and tissues of the face.

*Address correspondence to this author at the LoB5 Unit, Chonnam National University School of Dentistry, 77 Yongbong-Ro, Buk-Gu, Gwangju 500-757, South Korea; E-mail: LoB5@mac.com

Moreover, the surgery of the face is strongly interconnected with the plastic surgery: the skin of the face, more than any other area, needs the best possible healing. Fibrin glues were designed to improve healing and neoangiogenesis in the wounded site, and could be used without serious risks on most tissues: this polymorphic and adaptive tool was therefore a perfect surgical adjuvant, mimicking the natural coagulation process. Usable in small quantities in many different applications, it logically developed widely in oral and maxillofacial surgery.

When the fibrin glue technologies evolved into the PCs, it was first a way to replace expensive marketed fibrin glues by autologous preparations: the presence of the platelets reinforced the fibrin gel architecture, and blood bank fibrinogen concentrates were therefore no more useful. Once again, it is in plastic surgery (for the treatment of skin ulcers) that the concept of platelet concentrate was first described [12-14], and then quickly extended to all the oral and maxillofacial surgery [2]. But the true craze for growth factors started with the first article of Marx *et al.*, [3], and the quick development of these new techniques in oral and maxillofacial surgery is finally more related to commercial interest than to true scientific innovation: these preparations existed since many years and were used as improved autologous fibrin glues in other fields. With the Marx *et al.*, article, they started to have a common name - Platelet-Rich Plasma (PRP) - and to offer a new concept: growth factors [3].

The market was enormous, and this is how this field of research literally exploded in a few years, with an increasing number of techniques and devices proposed to the clinicians, and many home-made versions of the products [1]. Fibrin glues were logically substituted by PCs, but their distribution was much wider, surfing on the concept of growth factors as healing boosters. This craze for « growth factors » probably explain why so many companies developed user-friendly technologies, while the improvement of autologous fibrin glues was not a priority during the previous 10 or 20 years.

The collateral consequences of this development founded on beliefs and commercial interests more than on logical science, is that the literature on the topic is both wide and confusing.

2. WHAT DO WE USE IN ORAL AND MAXILLOFACIAL SURGERY? AN IMPOSSIBLE META-ANALYSIS

The field of platelet concentrates is very difficult to review, due to the absence of clear terminology during more than 10 years [1, 2, 15]. Many very different PCs were gathered under the term « PRP », without characterization of the products. Many authors seemed to consider that all platelet concentrates were the same whatever their content. A few studies tried to describe the content of these products, but only focused on platelets counts and main growth factors quantifications [16-21].

Platelet concentrates are in fact very difficult to characterize, because they are not a simple pharmaceutical preparation like antibiotics or anti-inflammatory preparations. PCs are blood extracts, manipulated blood clots: there are not a cocktail of some growth factors, they in fact concentrate thousands of actors that can interfere with the regulation of healing. This is the common point of all products: they are as

complex as blood coagulation itself, they are manipulated autologous tissues, a solid version of the blood, the circulating tissue [22-24].

For this reason, a PC must be analyzed like a tissue [22]. Indeed all these products can be classified in 4 big families followings 2 main parameters [1], common to all tissues: cell content and matrix architecture. The main matrix component of all platelet concentrates is the fibrin, but this matrix can considerably vary in terms of architecture [25]. The cell content is mainly related to the leukocyte concentration: most platelet concentrates are indeed platelet-leukocyte concentrates [26, 27], and leukocytes have a significant function in the biology of these products [28-36], even if they are too often neglected. Four families were thus defined [1]: P-PRP (Pure Platelet-Rich Plasma) and L-PRP (Leukocyte- and Platelet-Rich Plasma) are platelet suspensions, respectively without or with leukocytes, that can be used in a liquid form or in a gel form after activation using thrombin and calcium chloride (or batroxobin or other activators of platelets)[23]: the fibrin network of these family is always light and not very well structured. On the contrary, P-PRF (Pure Platelet-Rich Fibrin) and L-PRF (Leukocyte and Platelet-Rich Fibrin) are dense fibrin biomaterials, respectively without or with leukocytes, that only exist in a solid form with activated platelets [22].

A last parameter is the platelet concentration. Indeed, the various technologies offer different platelet collection performances [16, 17, 20]. This parameter can be significant when the platelet concentrate is injected as a liquid platelet suspension in a closed area, such as a tendon [37, 38]: in these applications, the product is used as a pharmaceutical preparation. On the contrary, in most oral and maxillofacial applications, the concentration parameter does not seem to be very important, because products are almost always used after activation into a gel and placed in an open surgical site with a significant bleeding: the blood flow, the edema water collection and the relatively large size of the open surgical site significantly dilute the impact of the platelet concentration. In this clinical field, the fibrin architecture [39, 40] and leukocyte content [41] of the material have logically a higher impact. Up to now, nobody has proven that evolutions of the platelet concentration parameter significantly change the clinical outcomes induced by these preparations in oral and maxillofacial surgery. The leukocyte concentration may also be a significant parameter, but this parameter has never been discussed yet.

In the literature about PRP and PRF in oral and maxillofacial surgery, the exact definition of the products tested in the various studies is often unclear, due to the lack of consensual terminology and to the associated misunderstandings [15, 42]. However, a careful evaluation of the published data reveals that L-PRP and P-PRP gels were probably the most frequent products tested in oral and maxillofacial surgery. In these clinical specialities, these products were never used without activation, contrarily to the injections of platelet suspensions used in orthopaedic surgery and sport medicine [37, 38].

It is difficult to identify the kind of PRP used in many studies, since the products are not well described or characterized. We can even suspect that many authors did not truly

understand the methodology they claimed to use, leading to an unknown and unreproducible product. However, it seems that L-PRP gels remain the main products tested. Indeed P-PRP are technically more difficult to prepare (since it requires a more efficient separation of the blood constituents), and only articles using a blood bank cell separator PRP or the Anitua's PRGF can logically be considered as P-PRP articles [1]: in oral and maxillofacial surgery clinical applications in human patients, this group of articles is nowadays marginal.

In the PRF families, only one publication described or tried to evaluate the use of P-PRF in oral and maxillofacial surgery [43]. On the contrary, most of the publications about L-PRF are related to oral [44-51], maxillofacial [50-56] and ENT (Ear-Nose-Throat) surgery [57-59].

3. HOW TO USE AND WHAT CAN BE EXPECTED FROM PLATELET CONCENTRATES IN ORAL AND MAXILLOFACIAL SURGERY?

The best way to review the current clinical results of these preparations in oral and maxillofacial surgery is first to understand what kind of effects are expected, and how the various families of preparations can be used in this wide clinical field.

There is an old surgery principle particularly true in all bone surgical disciplines: a surgical site with a good bleeding will heal correctly, while a site with limited bleeding will more probably suffer from infection, necrosis, or simply delayed healing. This surgical empirical principle can be explained very easily: a good bleeding allows the formation of a strong fibrin clot during the coagulation within the surgical site, and this matrix promotes an efficient neoangiogenesis [40], necessary for both wound healing and tissue remodeling [39] and also for immune drainage since the leukocytes can have a quick access to the surgical site and start cleaning and protecting it from infections. The concept of fibrin glues and platelet concentrates is logically to mimic and amplify this natural phenomenon, and even to replace it when bleeding is not efficient enough: they are first of all optimized blood extracts, prepared in a form that can be surgically handled and used. The expected clinical results in oral and maxillofacial surgery are dependent on the way we use it, but are always close to what is expected from an efficient and controlled bleeding and coagulation on a wounded site.

3.1. How to Use: the into/onto Bleeding Principle

Blood coagulation builds biological fibrin-based connexions within a wounded tissue or at the interface between tissues. Fibrin glues and platelet concentrates have thus to be used following the same principles. Whatever the oral and maxillofacial application, these fibrin gels are always used as biological connectors in order to amplify the natural function of bleeding: it was the principle of fibrin glues, it is also the core concept of PCs, even if growth factors are also expected to stimulate healing. These products can be used within a tissue or between tissues: this is the into/onto bleeding principle.

When the PCs are placed into a tissue, the purpose of the product is to connect the various elements (matrix and cells)

of the tissue, to accelerate neoangiogenesis within the tissue and its local remodelling. The best examples are bone or fat grafts: mixed with a PRP gel [3] or a PRF clot [48, 57, 59], the grafted tissue becomes more cell-migration-friendly, and that allows a quick angiogenesis, to avoid necrosis, and to limit infection development. Moreover, the various matrix components (fibronectin, vitronectin, glycosaminoglycans and fibrin itself) and growth factors of the platelet concentrates logically stimulate the «rebooting» of the grafted cells, their quick proliferation and/or differentiation, and the reconstruction and remodelling of the grafted tissue.

When the PCs are placed onto a tissue, the biological mechanisms are quite similar: blood connexion at the interface between 2 tissues, acceleration of angiogenesis in the periphery of the tissues and the associated stimulation of healing and remodelling. This basic mechanisms are similar between fibrin glues and platelet concentrates and are commonly used in plastic surgery for the stimulation of flap healing [60]. However, the clinical purpose may be a little bit more complex, since the function of these fibrin gel covers over a tissue is also the protection and quick closure of the wound. Placed at the interface between 2 tissues, the platelet concentrate will stimulate both: for example, when covering a bone graft on the dentoalveolar ridges, the platelet concentrates are supposed to stimulate the peripheral bone healing through the periosteum, but also to accelerate the soft tissue healing and remodelling, and therefore to avoid perforations of the weakened gingival tissues and the associated contamination of the bone graft below [54, 55]. Moreover, in other applications such as periodontal surgery, these fibrin layers may also have the function of a competitive barrier between several tissues competing for the colonization of a wounded site [61].

A last method is not to use platelet concentrate into the tissue, nor onto the tissue, but to use it as the tissue: some techniques (particularly L-PRF) allow to gather significant volumes of fibrin material and therefore to fill directly a surgical site and to promote the tissue regeneration, as it was already proven for sinus-lift bone regeneration [53, 56] or after tissue exeresis [52].

3.2. What is Expected: from the Theory to the Daily Practice

As a whole, in oral and maxillofacial surgery, platelet concentrates are expected to improve bone regeneration and soft tissue healing. Unfortunately, *in vitro* experimental data are quite contradictory on the effects of platelet concentrates on different kind of cells, particularly fibroblasts and osteoblasts. The analysis of these data has however to be considered carefully, because many of these studies present serious methodological mistakes related to the incomplete characterization (or even understanding) of the tested products: testing human PCs (sometimes containing leukocytes) in contact with bank cell lineages or cells from other species (without considering the immune identity of the cells), or testing unactivated platelet suspensions (while the products are always used after activation on a surgical site), or testing the cell effects without considering the key role of the fibrin matrix (particularly true with products from the PRF families); and sometimes all these intrinsic mistakes together in the same article [62, 63].

A careful analysis of the literature shows that these products induce generally a significant stimulation of the cell proliferation (at least for cells sensitive to platelet growth factors): osteoblasts [64-69], chondrocytes [70], periodontal cells [71, 72], fibroblasts [73, 74], endothelial cells [75], mesenchymal stem cells [76]. On the contrary, some articles demonstrated that PRP gels had no effect on the proliferation of fibroblasts and osteoblasts [77, 78], and even a negative effects on macrophages [79].

The impact on cell differentiation is more difficult to determine: most studies showed that PRPs stimulated the proliferation and inhibited the differentiation of osteoblasts [65], periodontal cells [80] and bone mesenchymal stem cells [81-83]. It is a quite logical result, since the tested cells were pushed toward a proliferative pattern by the platelet growth factors. However, the proliferation/differentiation patterns are very dependent on the test conditions in these *in vitro* models: proliferation may be followed by differentiation after cell confluence [67], a high platelet concentration may promote a negative effect on cell growth through saturation cytotoxicity [84], and a moderate platelet concentration may induce a few signs of differentiation [69, 85, 86]. However, these data have to be considered carefully, since they are the consequences of the limits of the *in vitro* cell models. Finally, it was also shown that the contact with platelet membranes and fibrin was an important parameter in the stimulation of proliferation [87] and even differentiation [88-90]: the architecture of the PRP fibrin gel is thus also an important parameter, even if it was too often neglected.

Even if the literature is difficult to interpret and presents contradictory results, this proliferation/differentiation balance may be considered as a basic rule for most platelet concentrates technologies: PRPs stimulate the proliferation and inhibit – or at least do not stimulate - the differentiation *in vitro*. This statement is not completely true, since high platelet concentrations can be cytotoxic *in vitro*, and differentiation can be promoted in specific *in vitro* conditions, particularly after contact with the fibrin clot of the platelet gel. This general rule with PRPs is moreover not true with L-PRF.

Indeed, L-PRF membranes induced simultaneously both stimulation and differentiation in a dose-dependent way within primary cell cultures from the same human donor as for the L-PRF [91, 92]. These 2 cell patterns were present and highly stimulated in the culture plate, both with osteoblasts [91] and bone mesenchymal stem cells [92], and the role of the leukocytes and the fibrin architecture was hypothesized to be the source of this very specific biological reaction. Moreover, no *in vitro* cytotoxicity effects were detected whatever the quantity of L-PRF used in the culture plate [91-93], probably because L-PRF interacts with cells like a solid biomaterial and not like a pharmaceutical solution (PRPs). Finally, the underlying cell mechanisms have yet to be understood, in order to prepare and use these products in the best possible way, and thus satisfy all our expectations.

There is however a last key expectation that will considerably influence the future of these products in the wide field of oral and maxillofacial surgery: clinicians need user-friendly procedures. Indeed, oral surgery is one of the most frequent surgery by number of acts, and a surgery with very

good outcomes. Since many basic oral surgery procedures give acceptable results without using adjuvants, the relevance of using platelet concentrates in daily practice is not only related to its clinical efficiency, but also to its cost and easiness of application. It was the same problem with fibrin glues: the advantages/inconvenients balance of these techniques has to be significantly positive in daily use.

Unfortunately, most of the platelet concentrate procedures are time-consuming, complex and expensive [1]. Like the species, surgical techniques evolve and the most efficient protocols only will survive over time. If the craze for growth factors was very strong in oral and maxillofacial surgery, the disillusion was also very quick, many clinicians considering that these techniques were too expensive and time-consuming for no or minimal clinical improvement. In the near future, simple and inexpensive techniques like the L-PRF will logically remain the major protocols used in oral and maxillofacial surgery. For this reason, and in order to describe these applications turned towards what we consider to be the future of the PC field in periodontal and dentoalveolar surgery, this article gives an overview of the results obtained with the various PRPs, but only illustrates clinical applications with L-PRF clots and membranes.

4. PRP AND PRF DURING TOOTH AVULSION AND CYST EXERESIS

4.1. Why and When Using PCs During Tooth Avulsion and Cyst Exeresis?

Tooth extraction or avulsion [94] is logically the most important and common surgical situation encountered in oral and maxillofacial surgery, and as old as human kind itself. This surgical procedure is more or less complex, but the outcomes are globally good. The use of a surgical adjuvant may seem unnecessary, but there are 3 configurations where a healing booster may be highly interesting.

The first situation is related to the postsurgical follow-up after complex tooth avulsion. For example, molars with divergent roots may require to cut the tooth in several pieces, with potential bone trauma (heat shock, mechanical shock) leading to significant pain, edema or even hematoma. It is also particularly frequent with the wisdom teeth, the third molar avulsion being very often associated with pain and swelling. The worst form of these minor postsurgical consequences is the osteitis, dry or infectious, and is associated to the delayed healing of the surgical site related to a lack of bleeding or to an instable blood clot within the avulsion socket.

The second situation is when implant restoration is considered after avulsion. The avulsion procedure must be as atraumatic as possible for the periodontal bone walls, and a complete and quick bone regeneration of the avulsion socket is expected in order to place implants in the best possible conditions. The healing and remodelling of the avulsion site is however highly dependent on the initial stabilization of the blood clot and the quick gingival wound closure.

The third situation is the avulsion in patients with general or local pathologies that interfere with bleeding or healing. It is particularly true in anticoagulated patients presenting a risk of delayed bleeding and healing, or in patients treated with biphosphonates presenting a risk of osteonecrosis of the

jaws. Compromised avulsion sockets presenting severe infection or necrosis are also good examples of local pathologies. In all these situations, a satisfactory healing is highly dependent on the blood clot stability and the quick soft tissue closure.

If these 3 situations are more often encountered with tooth avulsions, similar problems exist with cyst exeresis in the maxillaries. These cysts often have a dental origin, the cyst cavities and avulsion sockets are then often linked Fig. (1). In all these situations, the use of an optimized blood extract could amplify the natural coagulation process, and even replace it in case of insufficient local bleeding of the wound.

4.2. Current Experience with PCs in Alveolar Sockets and Cyst Cavities

The literature about platelet concentrates is quite limited about their use for the filling of tooth avulsion sockets and cyst exeresis cavities. The main reason is probably that these products are often expensive and time-consuming, and that many clinicians did not find interest in the use of these products in a daily application with good outcomes such as dental avulsion. There are however several good reasons to use some of these techniques as filling materials in most avulsion sites.

Several authors showed that PRP gel could significantly reduce postoperative pain and discomfort after tooth avulsion, and avoid the development of an osteitis [95-97]: this result was expected, since these products act as optimized blood clots and therefore allow a quick *in situ* neoangiogenesis and wound drainage. Moreover, the local bone stimulation associated with the growth factor release could counterbalance the bone traumatism due to the surgical procedure. The concentration of coagulation factors within the platelet gel was also used in order to control bleeding in anticoagulated patients [98]. However, the true relevance for the use of platelet gels in these applications was to accelerate bone regeneration within the avulsion socket and gingival healing: the purpose was not only to reduce discomfort and infectious risk, but also to increase the bone and periodontal tissue quality [99].

For example, after complex third molar avulsions, the bone defects can reach critical size and its natural regeneration can be compromised, with potential consequence on the periodontal tissue of the second molar. The use of a PRP gel was proved to improve healing in these sites, and guarantee a good outcomes for the neighboring tissues [97, 100, 101]. This application is however hotly debated, since some authors claimed that the use of a PRP gel within the avulsion socket of a third molar did not increase bone regeneration on the wounded site [102, 103]. It is however impossible to compare studies since the exact contents of the various products are often unclear.

Third molar avulsion is however not the main situation where an efficient bone regeneration is needed. The regeneration of an avulsion socket in order to place implant in the best possible situation was much more investigated. As a whole, the literature showed that PRP gels [97, 99] and PRF [43, 47] both increase bone regeneration when inserted in an

avulsion socket. These products also seemed to help for the decontamination of infected avulsion sites. However, it is difficult to draw very accurate conclusions concerning the best product for these applications, or even the best way to use it. When bone defects after avulsion are critical-sized (and often associated with cystic lesions), mixing the PRP or PRF with a bone substitute in order to use a significant volume of solid biomaterial for filling is considered as reliable option, even if the choice of the best materials remain unclear and debated [43, 104, 105]. These treatments are however no more simple dental avulsions, and are often at the border of Guided Bone Regeneration (GBR) or bone grafting.

4.3. Perspectives: L-PRF as Systematic Filling Material?

When considering the future of these applications, it seems obvious that nowadays most avulsions (except third molar avulsions) are followed by implant placement and that the preservation of the alveolar bone walls around the implants and the bone regeneration of the avulsion site are a medical obligation for a dental surgeon. The systematic use of a platelet concentrate in order to avoid painful events, promote bone regeneration and improve gingival healing may become a relevant principle in oral surgery. The main concern is that all PRP gels are expensive, time-consuming, not very easy to handle in daily oral surgery practice, and their filling volumes are often quite small. For all these reasons, it is highly probable that only a few techniques such as the L-PRF will still be used in these applications in the near future. The preparation of 8 L-PRF membranes or plugs is easy, requires only a small table centrifuge and less than 15 minutes. The plugs and membrane can be used to fill avulsion sockets, even when associated with severe cystic destructions after cyst exeresis [47, 106] Figs. (1 and 2), and allow a quick bone and gingival regeneration required for implant placement. It can also be mixed with a bone substitute and used as a protective cover over the grafted area: this is particularly important when gingival wound closure is impossible or difficult with the sutures Fig. (3). The function of the PRF membranes is then to stimulate gingival healing, but also to protect the bone graft from the oral environment and to maintain it within the avulsion socket, like a biological barrier: it is then not necessary to use more complex protocols for the protection of the filled socket (such as Guided Bone Regeneration (GBR) membranes and complex incisions, flaps and sutures) presenting high risks of negative outcomes, as it will be explained in the following chapters. Finally, the L-PRF technique is open-access and thus can be widely developed in private practice without commercial considerations.

Whatever the technique, platelet concentrates may be considered as an efficient option for the preservation of alveolar ridges, and the systematic filling of the avulsion sockets with a PRP gel or a PRF may become a standard procedure for a high-quality oral surgery in many situations. However, even for the user-friendly and inexpensive L-PRF technique, the choice of using systematically L-PRF in all avulsions remains highly dependent on the way of working and the philosophy of the surgeon. An expert periodontologist generally respects carefully the tissues and finds a great sat-

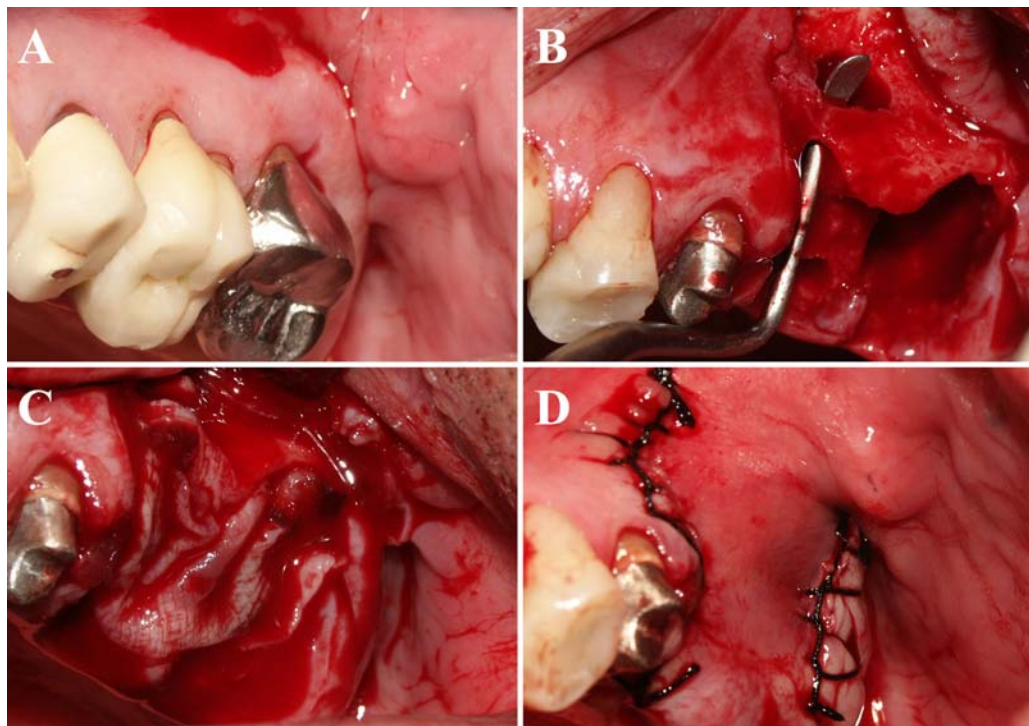


Fig. (1). Regeneration with L-PRF membranes of 2 maxillary avulsion sockets and cyst cavities. **A.** The first and second left maxillary molars were compromised because of the destruction of their supporting alveolar bone and a large cystic lesion. **B.** The 2 molars were avulsed and the cyst was removed carefully. The remaining bone walls were very thin and the bone defects were deep and large, thus presenting a significant risk of incomplete bone healing and fibrous invagination. **C.** The cyst cavities and alveolar sockets were filled with 4 L-PRF membranes for bone regeneration, and protected with 2 L-PRF membranes for the induction of soft tissue healing and remodelling. **D.** Tight sutures were performed in order to avoid membrane exposure and the contamination of the large regenerative chamber.

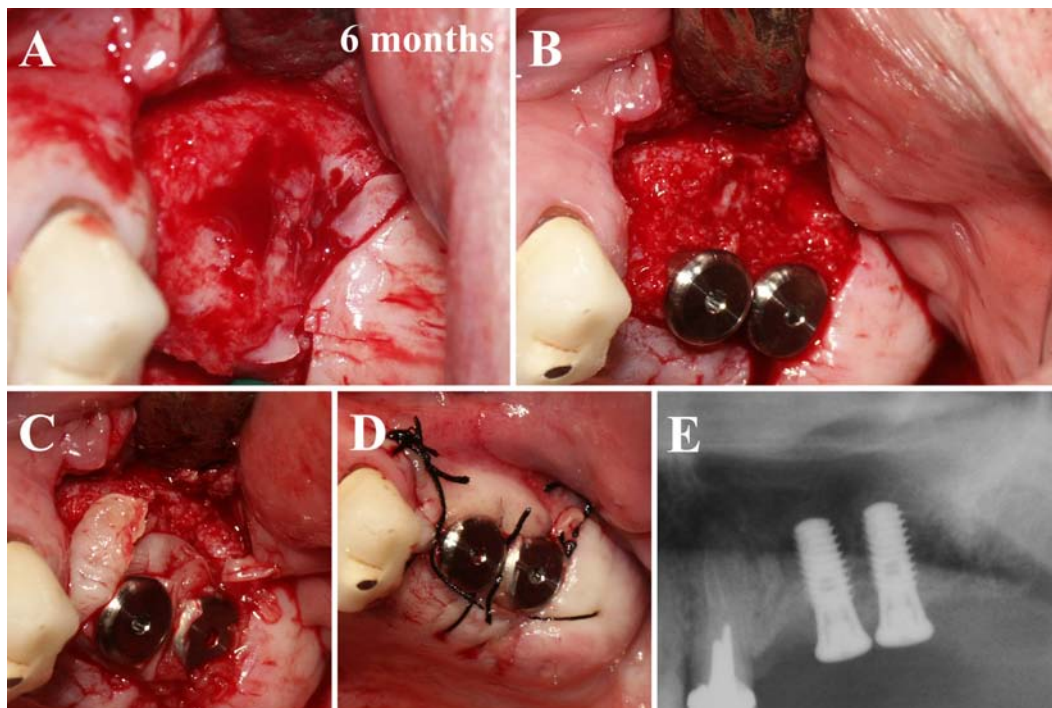


Fig. (2). Regeneration with L-PRF membranes of 2 maxillary avulsion sockets and cyst cavities. **A.** Six months after the filling with L-PRF, the bone defect was completely healed, with no trace of fibrous invagination. **B.** The regenerated bone volume allowed to place 2 long implants for the replacement of the 2 molars. **C.** L-PRF membranes were added in order to improve soft tissue healing and remodelling around the implants (multi-induction). **D.** Sutures were performed. The gingival maturation was already very strong after the first induction 6 months before. **E.** On the panoramic radiograph, the regenerated bone had the same density and aspect than the natural bone.

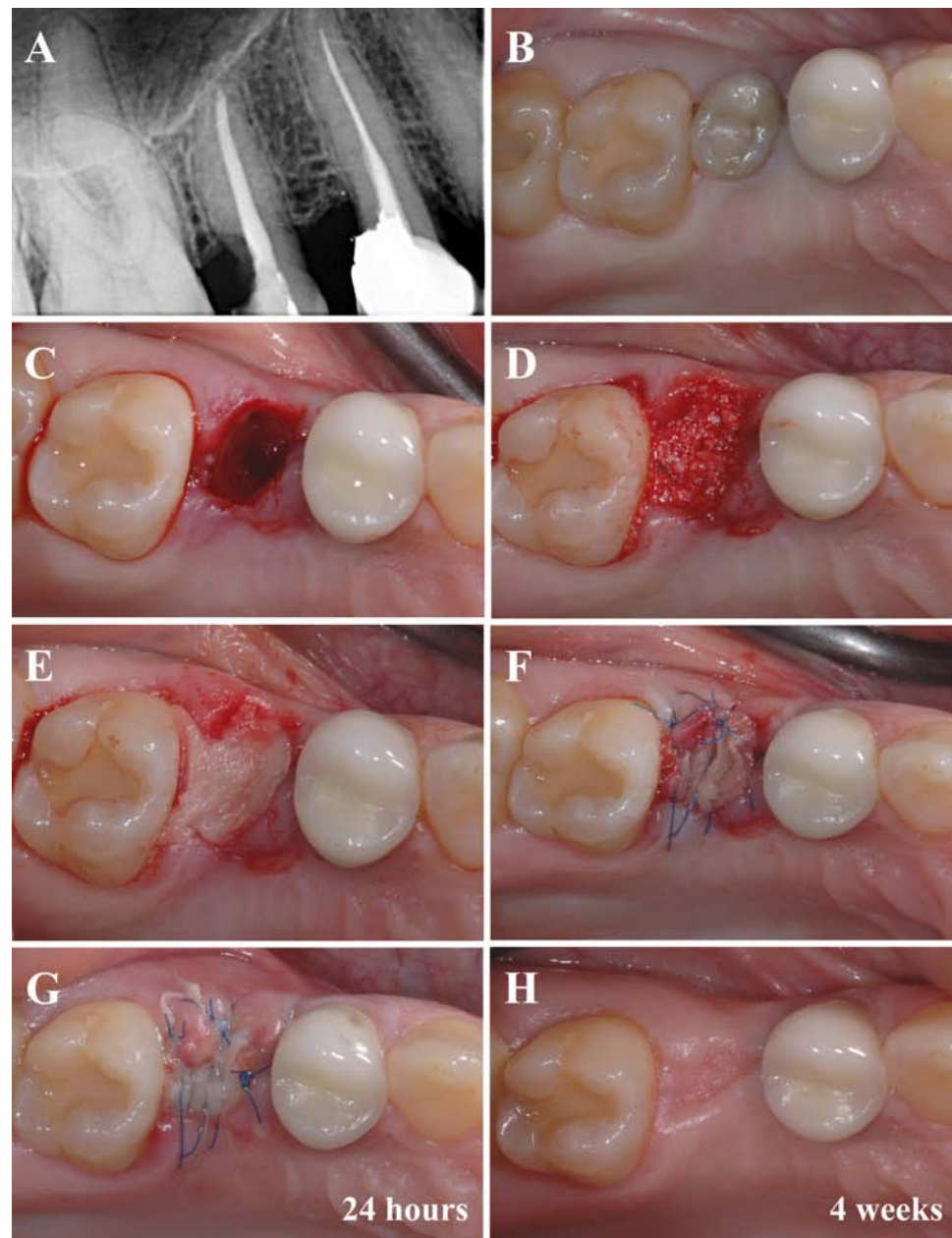


Fig. (3). Soft tissue regeneration of a filled avulsion socket protected with L-PRF membranes. **A and B.** Radiograph and clinical view of a damaged right second premolar. **C.** Atraumatic avulsion of the premolar and careful curettage of the bone socket. **D.** The alveolar socket was filled with a mix of L-PRF and xenogeneic collagenated bone (Gen-Os, OsteoBiol, TecnoSS, Italy) in a 50/50 volumic ratio. **E.** A L-PRF membrane was folded in 3 layers, tailored and placed above the filled avulsion socket. **F.** Multiple sutures were performed in order to block tight the L-PRF membrane on the grafted area, and to stabilize the folded membrane edge to edge with the wound borders. The external L-PRF layer remained in contact with the oral cavity. **G.** After 24 hours, the gingival tissue was proliferative, the superficial re-epithelialization on the L-PRF membrane and the wound closure were on progress, triggered by the initial induction. **H.** After 4 weeks, the filled avulsion socket was completely closed. The induction and merging phases were over, and the tissue started the slow and long remodelling phase that lasted until the complete regeneration of a thick gingival tissue. The avulsion socket was regenerated without the use of GBR membranes, complex incisions, flaps and sutures, and their associated risks of negative outcomes.

isfaction in using biomaterials such as L-PRF to control and increase the healing potential of the alveolar socket. On the contrary, a more generalist oral and maxillofacial surgeon may have a more simple approach and let the tissues heal naturally: in simple cases, it will indeed not considerably influence the final outcome of the treatment. This is an old debate between periodontologist and general oral surgeons,

about the level of care expected for the periodontal tissues during an avulsion. In fact, for each case, the size of the bone defects, the quality of the gingival tissue and the expected implant treatment will guide our advantages/inconvenients balance, in order to determine if platelet concentrates can be useful. This is however a question of therapeutic philosophy and habits: simplified and efficient methods such as the L-

PRF technique are already used by many surgeons almost systematically during tooth avulsions.

5. PRP AND PRF FOR THE REGENERATION OF PERIODONTAL BONE DEFECTS

5.1. A Comprehensive Analysis of the Contradictory Results with PRP Gels

The second logical application after avulsion socket filling for bone regeneration, is to regenerate bone and gingival tissues around teeth presenting periodontal damage. Most studies were performed with PRPs, but the exact content of the various tested products remains largely unknown, the published data thus being difficult to fully sort and interpret. The reported results with PRPs are quite contradictory [107].

Many authors reported that during the filling of a periodontal intrabony defect with autologous bone or a bone substitute (allograft, xenograft or synthetic material), the addition of a PRP to the grafting material always offered good results [108, 109], but failed to prove any benefits in the reduction of pocket depth, for clinical attachment gain and defect fill [110-114]. The explanation of this result is in fact quite simple: a periodontal intrabony lesion is always relatively small, and during the filling with a bone material, this latter can easily be impregnated with the peripheric bleeding on the surgical site ; the addition of some more platelets may not influence considerably the final biological equation in this kind of wounded site.

On the contrary, some other authors showed that the use of a PRP with a grafting material could promote better results in these applications [115-117]. However, some authors claimed that this improvement induced by PRPs was not related to bone healing, but only related to soft tissues parameters [118].

These contradictory results may seem difficult to analyze and understand: the tested PRP gels were not fully characterized and the clinical situations, the surgeon skills and grafted bone substitutes were never exactly the same, leading to an impossible exact comparison, and thus no evidence-based conclusion. However, after careful evaluation of the publications, these contradictions may be explained by the conditions of clinical use of the PRP gels: the PRP gels were indeed efficient when also used as a cover above the filled intrabony defect. This result seems quite logical, since the coverage of the grafted bone defect with a fibrin gel necessarily promotes soft tissue healing and the protection of the surgical site, leading to the acceleration of the wound closure, and a more secure bone regeneration.

Another approach was to fill the intrabony defect with a PRP only. However the results were again quite contradictory. Some authors showed that the filling with a PRP gel alone achieved a similar bone regeneration than the use of a membrane for guided tissue regeneration [119, 120] or even than the filling with a bone substitute [121]. However, other authors demonstrated that PRP alone was not able to support a significant bone regeneration [122] and that PRP should be associated to other materials in order to give good results for the healing of periodontal lesions [123]. The comparison of the data is difficult since the kind of PRPs used in these studies is once again difficult to determine, but these contradic-

tory studies suggest that the size and form of the defect significantly conditioned the true potential of the platelet con-

centrate. PRP gels are indeed fragile and soft filling material, and are thus highly sensitive to mechanical constraints. When the intrabony defects present several walls and are easily protected, a platelet gel acts as a stabilized blood clot and therefore becomes the perfect filling material for a natural tissue regeneration. This kind of treatment is obviously more natural and therefore better than filling with a bone substitute that will require many years to resorb and remodel, even if the sole objective of clinical tooth stability is the same with both approaches. But when the local conditions are not optimum, PRP gels alone are not strong enough to promote a clinical filling equivalent to the dense bone filling reached with a bone substitute. Some authors hypothesized that the good clinical results obtained with a PRP gel alone may be related to the higher platelet concentration of their tested product [119, 124]; this argument is however debatable, since these authors did not fully characterize the tested platelet concentrates (leukocyte content and fibrin architecture), and since similar results were obtained by other teams with other PRP gels.

The last approach was to use PRPs during Guided Tissue Regeneration (GTR). GTR requires various kinds of membranes (non resorbable such as expanded polytetrafluoroethylene membranes (ePTFE) or resorbable such as collagen membranes) in order to protect the bone defect after cleaning, debridment and sometimes filling, to stabilize the blood clot and to protect the filled defect from soft tissue invagination. The concept of GTR is therefore to promote the regeneration of periodontal tissues in a natural architecture: bone, periodontal ligament and gingival attachment. Unfortunately, the use of these membranes required skillfull surgeons and often led to delayed soft tissue healing, particularly when using non resorbable membranes.

Some authors showed that the use of PRP and a bone substitute as filling material in addition to the GTR membrane gave very good results [125, 126], and even better results than GTR membranes alone [127]. However, most of the clinical outcomes seemed to be related to the bone filling material: indeed, the addition of a PRP gel to a classical treatment using bone substitute and GTR membrane did not improve the clinical results, whatever the kind of membrane (ePTFE, collagen) or material (autologous, anorganic bovine bone, etc...) tested with the PRP gel [128-131]. The explanation is once again intrinsically simple: the purpose of the GTR membrane is to protect the filled intrabony defect from soft tissue invagination and to stabilize the blood clot in the bone cavity ; the addition of some more platelets under the GTR membrane does not interfere with the functions of the membranes, and does not significantly influence the natural blood clot impregnating the filling bone substitute. However, some authors showed that the PRP gels could also be used as sole filling material under a GTR membrane, with similar results that the filling with various bone substitutes under the GTR membrane [124]. This result is quite logical and expected, since PRP gels are stabilized blood clot and thus are the ideal filling material under a GTR membrane. As a summary, PRP gels could be used as sole filling material under a

GTR membrane, but there is no specific improvement when using PRP and bone substitute together under a GTR membrane.

However, there is a last way for the PRP gels to improve the healing equation during GTR: they could be injected above the GTR membrane in order to improve the soft tissue healing and remodelling, and thus to avoid soft tissue dehiscence; PRP gels would then only serve as soft tissue healing stimulator and barrier. The logical question is then to understand in which conditions the PRP gels can become a barrier able to replace the GTR membrane: this concept was highlighted in a study where the filling of periodontal intrabony defects using a bone substitute with a PRP gel promote similar results with or without GTR membranes [132]. In some situations, some PRP gels may thus replace not only the filling materials, but also become a true protection membrane.

From a more experimental standpoint, many authors had shown that periodontal ligament cells were highly receptive to the platelet growth factors for proliferation, and that the fibrin platelet gel probably also contributed to the stimulation of their differentiation [88-90]. Some studies therefore tried to evaluate the use of engineered membranes associating periodontal cells and PRP for the treatment of periodontal intrabony defects. The simplest approach was to coat various kind of membranes (non resorbable Gore-Tex or resorbable collagen membranes for example) with a PRP, in order to load it with growth factors and attachment proteins, and therefore to create a personalized membrane with the patient's own stimulating factors. This approach indeed allowed to stimulate the attachment and viability of gingival fibroblasts [133], and could be easily used in daily practice. A more complex approach was to use human cultured periosteum sheets associated with PRP and a bone substitute for the treatment of intrabony defect [134, 135], or even to use adipose derived stem cells with PRPs as filling materials [136]; the use of such tissue-engineered grafting materials gave good results, but is obviously too expensive and complicated in daily periodontology practice.

The field of periodontal intrabony lesions is quite wide with many different potential applications. For example, the treatment of periapical inflammatory lesions with a bone substitute associated with a PRP gels was often described, even if the true impact of the PRP on the healing remained quite difficult to assess [137, 138]. A last original application of PRP gels in periodontal regeneration was to coat an avulsed tooth with the PRP before replantation in the avulsion socket [139, 140]. This concept is interesting, but its clinical relevance should be more carefully evaluated.

As a conclusion, the numerous publications about the use of PRP gels for the filling of periodontal intrabony defects were quite contradictory, but were able to guide us towards new principles of treatment, beyond simple fillings or complex GTR. Indeed when using GTR protocols, the published data allow to consider that the PRP gels could be used a sole filling material below the membrane, and as soft tissue healing booster above the GTR membrane. But since it was proven that when using a PRP gel with a bone substitute for the filling of periodontal intrabony defect, the addition of a GTR membrane was probably no more required [132], we could conclude that in some situations, some PRP gels may

therefore become a true protection membrane. This conclusion implies very important consequences for the future of these techniques, and the development of efficient and simplified procedures for the treatment of these lesions. As soft tissue healing booster, intrabony stabilized blood clot and tissue barrier, the selection of the adequate platelet concentrate gels may allow the development of a new kind of GTR: as it is described below, this is the concept of Natural Tissue Regeneration (NTR) developed with L-PRF clots and membranes.

5.2. L-PRF and the General Principles of NTR (Natural Tissue Regeneration)

Contrarily to PRP gels, the products from the PRF sub-families were not widely analyzed yet in the international literature for the treatment of periodontal intrabony defects. However, for obvious reasons, these techniques are the future of the field: a L-PRF is an autologous strong fibrin membrane, loaded with autologous cells (leukocytes, circulating stem cells)[22] and enriched with growth factors and matrix proteins that are released during at least 7 days [141, 142]. The L-PRF technique [143] is very simple, inexpensive, and allows the quick production of at least 8 strong fibrin membranes [44].

Such a membrane holds intrinsically all the solutions to the problems encountered with classical GTR techniques. These latter are sensitive and operator-dependent; collagen membranes are xenogenous and thus their use is dependent on the patient's acceptance of bovine or porcine tissue implantation; non resorbable membranes such as ePTFE present a very significant risk of delayed wound closure and soft tissue dehiscence, leading to the membrane contamination and to local tissue necrosis and associated severe outcomes. For all these reasons, the attractive natural concept of the GTR was often replaced by a simple defect filling with bone substitutes; however this solution does not fit to all clinical situations where GTR could be used. Moreover, GTR and fillings are not recommended in patients with habits or diseases that interfere with soft tissue and hard tissue healing: smokers, non equilibrated diabetics, patients under anticoagulant therapies, etc., even if these patients are often suffering from periodontal intrabony defects; there is indeed a significant risk of delayed healing and necrosis when the general terrain is not adequate. Finally, the addition of PRP gels, time-consuming and expensive techniques, did not truly change the global equation of these treatments. The evolution of these techniques was thus too often the avulsion of the severely compromised teeth and the rehabilitation with dental implants. To evolve or to disappear, this is the actual problematic of GTR.

On the contrary, L-PRF membranes have strictly no contraindications, they can be used in all kinds of patients (and can even be recommended in patients under anticoagulants or smokers), they always promote soft tissue healing (even when the membranes are not very well handled by a rookie surgeon), and they can stimulate the healing of a damaged flap and reduce the risks of flap necrosis after a surgery. It is a common point with all fibrin-based products, particularly the fibrin glues used for the stimulation of angiogenesis and to reduce the risk of flap necrosis in many general surgery applications [39, 40, 60]. In order to see the full potential of

these L-PRF membranes, an adequate surgical technique is however required, even if no negative effects have to be feared.

The concept of NTR is to promote the regeneration of the various periodontal tissues required for a normal tooth function (bone, periodontal ligament, gingival attachment) with L-PRF membranes as filling material and protection membrane, most times in association with a bone biomaterial as space maintainer. The NTR is often combined with a metronidazole solution soaking the filling material in order to protect the bone healing compartment from the unavoidable bacterial contaminations [144].

L-PRF membranes are not comparable to resorbable collagen or non-resorbable ePTFE membranes, they belong to a completely different category of membrane [145]. However, the difference between GTR and NTR is not only the replacement of the various heterologous membranes used in GTR by a new kind of natural autologous membrane: it is also a true evolution of the concept behind. Indeed, L-PRF membranes are optimized blood clot, and therefore their interactions with the tissues do not follow strictly the core principles of GTR: GTR membranes had to stabilize the blood clot and to create a cell-proof barrier against soft tissue invagination, a NBR membrane is the blood clot itself (therefore rich in cells) and is only a bioactive competitive barrier. While other membranes are considered as foreign bodies by the host tissues and interfere with the natural tissue healing process, a L-PRF membrane is as natural as the host tissue: it is a blood clot prepared in an optimized form and that can be easily handled by a surgeon.

The general principles for the use of L-PRF for the treatment of a periodontal intrabony defect are quite similar to what was already discovered with PRP gels, with however several key modifications.

First, L-PRF is an optimized blood clot with stronger fibrin architecture and mechanical properties than a natural blood clot or a PRP gel; these latter are considered as the core regeneration tissue in GTR, and L-PRF can thus theoretically be used as a filling material in intrabony defects when these very same GTR principles are followed [53, 56]. In comparison of a natural blood clot or a PRP gel, a L-PRF membrane is a solid material easier to handle and to position in the defects, and this is also a considerable advantage.

Second, L-PRF membranes can also be used as protection membranes after the filling of the intrabony defect. In comparison to GTR membranes, L-PRF will undergo a quicker remodelling *in situ* than a resorbable collagen membrane, but also promote a strong induction on the gingival tissue due to the slow release of growth factors and other matrix proteins [61, 141, 142].

Third, the L-PRF membranes should not be used as a complete cell-proof barrier: they act as a competitive barrier [61]. Contrarily to GTR membranes (particularly ePTFE), L-PRF membranes allow cells to migrate through it, and therefore allow neoangiogenesis and interactions between the bone alveolar ridges and the gingival flap. These interactions are very important during tissue regeneration, since the periosteum covers the internal part of the gingival flap and is a

key actor of bone healing and gingival maturation. While GTR membranes block the periosteum healing potential and bone/gingival interactions, the L-PRF membranes stimulate the periosteum regenerative properties. However, even if L-PRF membranes do not block the migration of the cells, no invagination of the soft tissues within the bone area were observed when L-PRF membranes covered a filled intrabony defect [53, 56]. This result is the consequence of a biological mechanism called competitive barrier: the L-PRF membrane is a highly stimulating matrix, attracting cell migration and differentiation preferentially, and also reinforcing the natural periosteal barrier; the hard and soft tissues migrate and interact within the L-PRF matrix, the L-PRF cover becomes the interface between the tissues and therefore avoids the migration of the soft tissues deeper within the bone defect. This concept of competitive barrier was already developed in maxillofacial surgery during the filling exeresis cavities with a large volume of L-PRF clots, these latter being also used as an interposition material between the gland/skin complex and the deeper tissues (particularly the nerve trunks) [52].

These 3 biological mechanisms associated with the use of L-PRF membranes must be understood in order to follow correctly the key principles of NTR. Clinically, the general concept of NTR requires to fill the periodontal intrabony defect with L-PRF, most times in association with a bone substitute used as a solid space maintainer, and then to cover the filled intrabony defect with L-PRF membranes, used for the protection of the grafted area and as a healing booster for the soft tissues above the defects Figs. (4 and 5). The objective of this cover is not only to protect the blood clot and/or the filling material, like in the GTR concept, but also to promote the induction of a strong and thick periosteum and gingiva: this boosted periosteum functions as a true barrier between the soft tissue and bone compartments, and constitutes probably the best protection and regenerative barrier for the intrabony defects Fig. (6). The NTR protocol is very simple and give excellent results in most clinical situations, with no contraindication or risk of negative effects. However, in order to get the best results, the choice and the quantity of the adequate bone substitute has yet to be determine in various clinical configurations.

6. PRP AND PRF ON SOFT TISSUES: ROOT COVERING AND GINGIVAL SURGERY

6.1. Gingival Surgery and PRP Gels: Understanding the Contradictions

Bone healing is a long-term phenomenon, and for this reason, the impact of PRPs on bone remodelling is hotly debated. On the contrary, the effects of the platelet concentrates on soft tissues reached a consensus very quickly, and with a quite small quantities of published data. These products always stimulate soft tissue healing and wound closure, and they are often used for these properties. The best examples were reported in plastic surgery, where platelet concentrate gels and fibrin glues were commonly used for the stimulation of skin healing and to avoid the necrosis of flaps [6, 60]. In the literature, it is also difficult to know if PRP gels and fibrin glues present true different effects on soft tissue healing, even if the role of platelets can anyway only be positive.

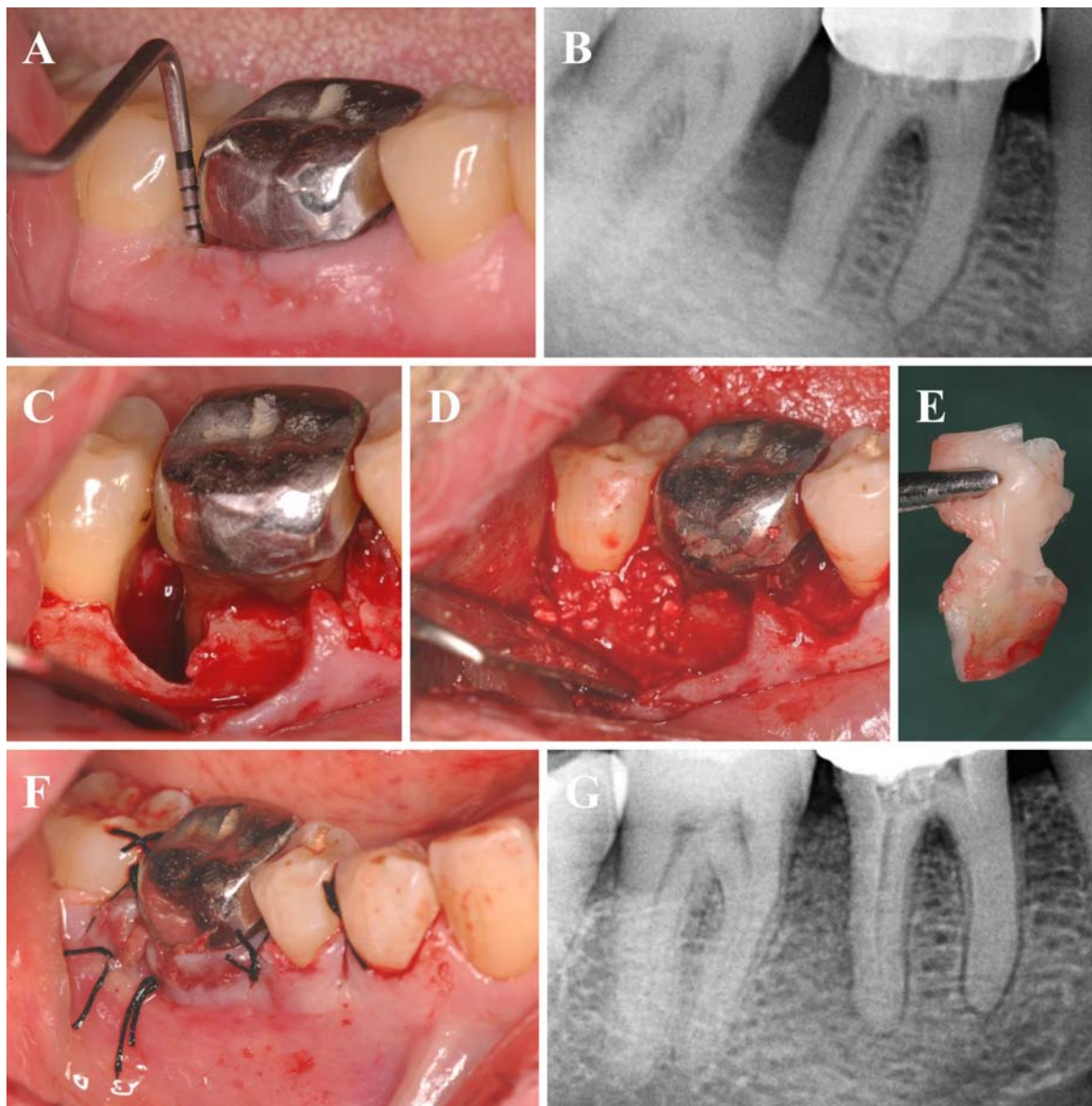


Fig. (4). Natural Tissue Regeneration (NTR) around a mandibular first molar. **A.** The first molar was compromised by a distal deep intrabony lesion, with a probing depth around 16mm. **B.** The retroalveolar radiograph confirmed that the intrabony lesion almost reached the apex of the distal root. **C** and **D.** The intrabony defect was carefully cleaned, and filled with a mix of L-PRF and xenogeneic collagenated bone (Gen-Os, OsteoBiol, Tecross, Italy) in a 50/50 volumic ratio, in association with a 0.5% metronidazole solution. **E.** A L-PRF membrane was tailored in order to cover the filled bone defect and to fit to the narrow interdental space. Another membrane was placed around the tooth in order to increase the gingival healing and remodelling on the mesial area of the flap. **F.** Deep sutures were performed in order to stabilize tightly the flap. **G.** The first postsurgical radiograph confirmed the complete filling of the intrabony defect.

In oral surgery, the effect of platelet concentrates on soft tissue healing was more debated, probably because the natural healing potential of the oral cavity is already very high. During oral mucosal wound healing, the PRP gel has a strong stimulant effect on capillary regeneration, and this effect was proved to be particularly strong during the early stages of wound healing [146]. However, gingival surgery does not only require a good soft tissue healing, but also to promote a strong remodelling. Preliminary results with PRP gels in animal models suggested that the addition of PRP gel on a gingival flap did not significantly improve the flap tensile strength [147], and therefore maybe not influence the

final gingival tissue remodelling. Whatever this very limited number of experimental results, many authors tried to use the PRP gels as a surgical adjuvant in order to improve the wound closure, and with good outcomes [96, 148].

The applications of PRP gels in gingival surgery however require a more in-depth analysis. Soft tissue periodontal surgery is indeed very technical, the purpose being often to improve the quality of the gingival tissue, or to cover gingival dehiscence/recessions around teeth through the promotion of a tissue attachment on the bare dental roots. The idea of using platelet for a better soft tissue attachment on the root surface is quite old [149], and the use of fibrin derivatives

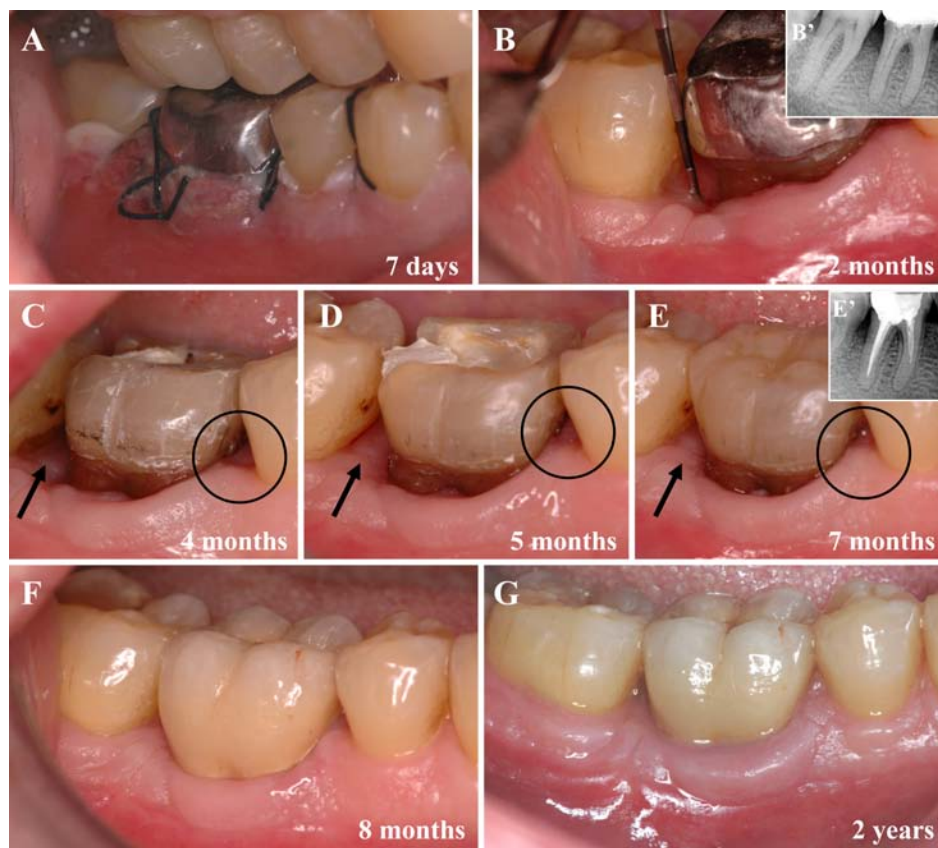


Fig. (5). Natural Tissue Regeneration (NTR) around a mandibular first molar. **A.** Seven days after surgery, the gingival flap presented a typical whitish proliferative aspect: this is the induction phase. **B** and **B'**. Two months after surgery, the probing depth was stabilized above 2mm. The gingival tissue showed a typical thick and inhomogeneous surface due to active remodeling. The retroalveolar radiograph confirmed the stability of the intrabony filling. **C, D** and **E.** The remodelling of the gingival tissue around the molar was followed and carefully evaluated respectively 4, 5 and 7 months after surgery. The mesial (black circles) and distal (black arrows) interdental gingival tissues continued their slow remodelling and growth triggered by the induction. **E'**. The retroalveolar radiograph confirmed the stability of the intrabony filling after seven months. **F** and **G.** The final prosthetic crown was placed on the molar, with open interdental spaces respecting the remodeling and growth of the interdental gingiva. The periodontal remodelling was then followed during 8 months and 2 years after the surgery, and the gingiva slowly continued its slow evolution and reached a very stable final aspect.

was also suggested in periodontal research as a potential matrix for gingival healing and attachment [150]. Various PRP gels were therefore tested in addition to common soft tissue periodontal surgical treatments, and the results are quite contradictory [151]. The addition of a PRP gel during a connective tissue graft for root coverage was investigated in a few articles only: some authors concluded that the addition of a PRP gel did not seem to improve significantly the final clinical results [152], while other authors proved the contrary with histological sections [153], and some other authors were simply not able to reach clear clinical conclusions [154]. Another clinical situation was the use of a PRP gel for the protection of the palatal donor site following a connective tissue harvesting, and some authors tried to show that the addition of a PRP gel did not improve soft tissue healing [155]. This dog study however was biased since the main parameter was not assessed: indeed, the main issue with palatal harvesting is not the healing (particularly with dogs presenting intrinsically a very quick soft tissue healing) but the pain associated with the surgery, and pain was obviously not assessed with this animal.

Clinical reports suggested that the potential benefits of PRP gels in root-coverage procedures and gingival surgery may be improved esthetics, decreased patient morbidity, and accelerated wound healing. But these statements are difficult to validate through the international literature. However, the lack of detailed proofs does not mean that PRP gels are not useful in gingival surgery. The exact content and architecture of the PRP gels tested in the literature are often unclear, the methods of application are not always very « biology-friendly ». We know for sure that the PRP gels have at least the same positive actions than the fibrin glues in terms of stimulation of healing. But it seems quite clear that, considering the cost and time loss associated with most PRP techniques, the addition of a PRP gel in most periodontal soft tissue surgeries does not present sufficient advantages. The situation is completely the contrary with the L-PRF membranes.

6.2. Gingival Surgery and L-PRF Membranes: Induction, Impregnation and Remodelling

Contrarily to the various PRP gels used as surgical adjuvant, the L-PRF membranes present a strong fibrin matrix

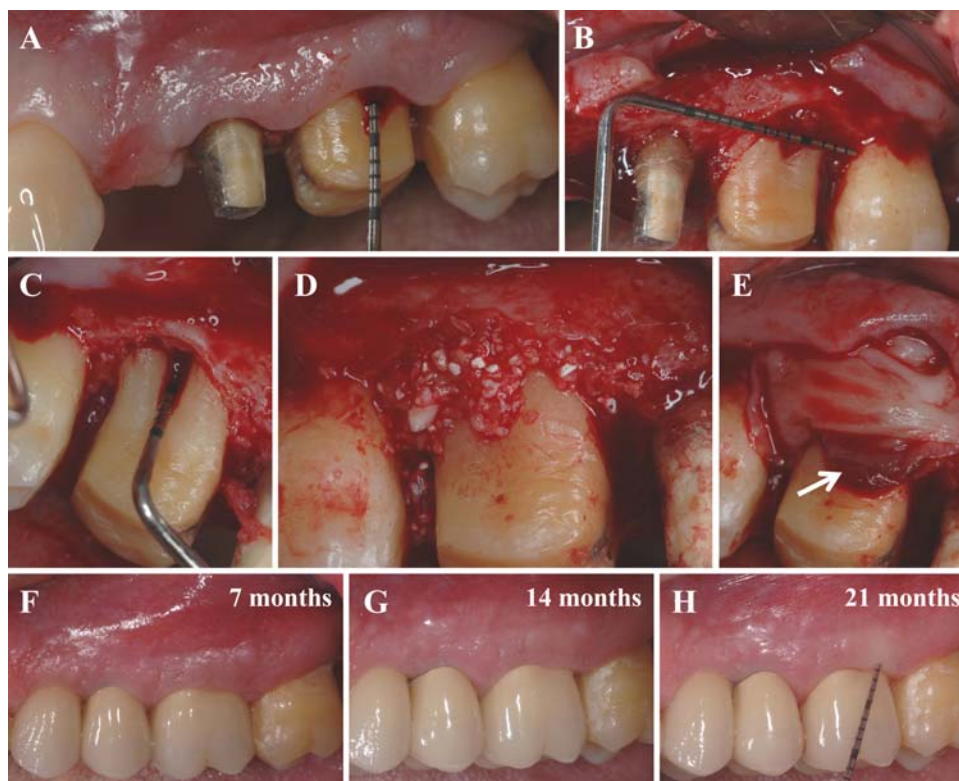


Fig. (6). Natural Tissue Regeneration (NTR) around a maxillary first molar. **A.** The molar presented a deep intrabony defect, with a probing depth around 10mm. **B** and **C.** This lesion was very difficult to treat because the defect was all along the vestibular face of the tooth and extended on the mesial and distal faces of the root. **D.** The fibrous tissues within the intrabony defect was carefully curetted. The clean intrabony extended cavity was then filled with a mix of L-PRF and xenogeneic collagenated bone (Gen-Os, OsteoBiol, TecnoSS, Italy) in a 50/50 volumic ratio, in association with a 0.5% metronidazole solution. **E.** Three L-PRF membranes were used to cover the surgical site. Care was taken to envelop also the mesial and distal faces. The leukocyte-rich areas of the 3 membranes were shared between the 3 areas of the lesion: one distal, one mesial and one covering the vestibular face (white arrow). **F, G** and **H.** This tooth was carefully controlled at 7, 14 and 21 months respectively, and this follow-up showed a strong remodelling of the gingival tissue, with a thick attached gingiva and a final stable probing depth inferior to 2 mm around this tooth.

[22] and are thus easily handled like a soft tissue graft during a periodontal surgery [61]. The L-PRF membrane can be tailored and sutured, and this specific form opens a wide range of possibilities, particularly in gingival surgery where very thin grafts, flaps or membranes are commonly handled: tissue manipulation is the key concept in gingival surgery, and a L-PRF membrane is a solid tissue with a matrix and cells, and thus perfectly fits to this purpose.

A L-PRF membrane is intrinsically very different from the various PRP gels previously tested. First, when the production techniques is followed carefully, the exact content and architecture of the membrane is well known [22], while the identity of most of the PRPs tested in the literature remains widely unclear [1]. Second, the L-PRF membrane presents a strong fibrin architecture that allows to use it as a true membrane or tissue [53-56], while PRP gels are only used as a transitory fibrin layer added to the surgical site [23, 155]. Third, a L-PRF membrane releases growth factors and matrix proteins during more than 7 days [141, 142, 156, 157], while the PRP gel matrix disappears quickly and releases all the growth factors in a very quick download. A PRP gel is a transitory pharmaceutical adjuvant, a L-PRF membrane is a solid biomaterial. These key characteristics

have to be taken into consideration during the development of clinical methodologies.

In order to get reliable results, L-PRF membranes must not be considered as a « magical » adjuvant to the surgical procedure, but must become the main instrument of the regenerative procedure. This difference of conception was clearly pointed out in a recent article: while some authors claimed to get a limited improvement of the root covering with a L-PRF membrane used as an adjuvant to the common procedure, it was shown that the use of the L-PRF membrane as the central actor of the regenerative procedure leads to clinical results, in terms of root covering and tissue remodeling and thickness, that could not be reached with common procedures (even when associated with PRP gels)[61]. These very good clinical results are obvious for all trained periodontologists using L-PRF, as shown in Figs. (7 and 8).

The property of slow release of growth factors and matrix proteins from the L-PRF membrane promotes 2 specific biological mechanisms during root covering: impregnation and induction [61]. First the root surface is impregnated with blood proteins, which are the first biological links between the surface and a new attachment: this is an old validated concept in periodontal surgery [149]. Second, contrarily to

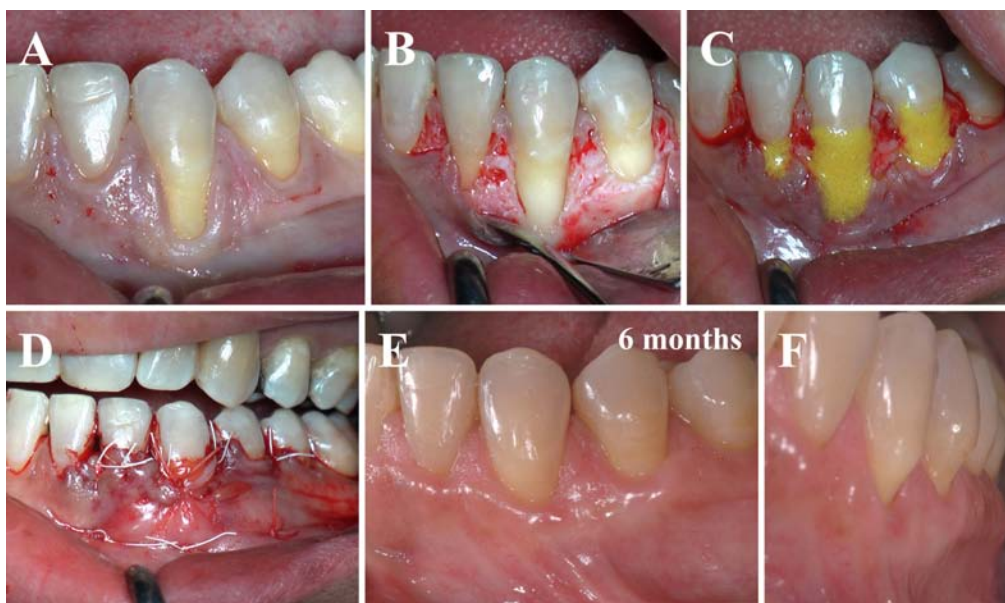


Fig. (7). Gingival root covering surgery using L-PRF membranes as grafted tissue around a canine. **A.** This mandibular canine presented a significant vestibular dehiscence. The classical treatment could be the coronal repositioning of the flap, often associated with a connective tissue graft in order to obtain an adequate height of attached gingiva: on the contrary, it was decided to use L-PRF membranes as sole grafted tissue. **B.** The partial thickness flap uncovered the deep gingival recession. **C.** The root surface was decontaminated and treated with a tetracycline solution (yellow). **D.** Three L-PRF layers were placed on the root, above the cemento-enamel junction, and the flap was then sutured coronally. The flap seemed swollen due to the volume of the 3 L-PRF membranes. **E** and **F.** Six months after the surgery, the clinical root covering was stable, high and very natural. The gingival induction and remodelling led to a thick attached gingiva.

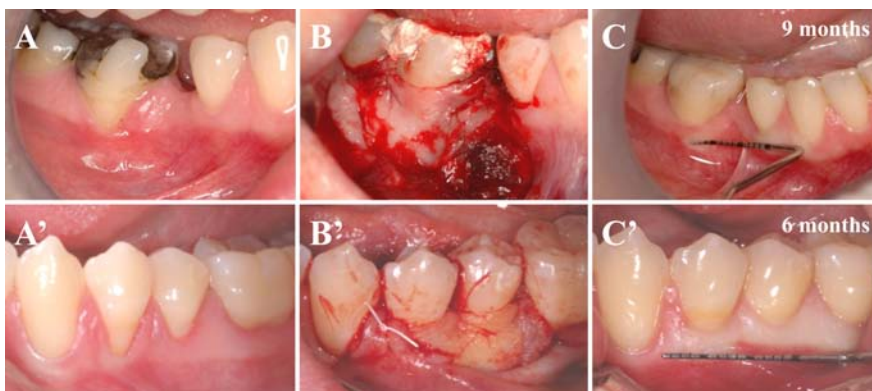


Fig. (8). Gingival root covering surgery using L-PRF membranes as grafted tissue around a molar and premolar. **A** and **A'**. Limited gingival dehiscences were observed, respectively on a mandibular first molar and 2 mandibular premolars. **B** and **B'**. In these simple cases, 2 L-PRF membranes were used as tissue graft per case, and placed on the roots above the cemento-enamel junction before the coronal repositioning of the flap. **C** and **C'**. The clinical root covering, respectively after 6 and 9 months, was complete in both cases, with a very natural and thick attached gingiva.

PRP gels, the slow release of molecules from the L-PRF membrane lasts several days [141, 142] and thus is long enough to trigger a cell induction phenomenon [91, 92]. The growth factors stimulate cell proliferation, neovessels develop within the fibrin matrix, the periosteum is stimulated, the gingival fibroblasts migrate within the fibrin matrix and slowly remodel it, while the membrane guides surface epithelialization if needed: this matrix offers a new scheme of development to the natural tissue. The short term result is a quick wound closure and healing [47], with the reduction of postsurgical pain and edema [54, 55]. The long term result is not only a stable root covering, but also a thicker stable gin-

giva [61]. It is interesting to see that this phenomenon of induction continues to show effects several months after the end of the surgery, until the final development scheme triggered by the L-PRF membrane is complete. It was also shown that the repetitive use of L-PRF membranes for soft tissue healing even amplified the final tissue remodelling, and thus that multi-induction was possible [54, 55]. If very good healing properties were always observed in these procedures, the underlying induction and remodelling mechanisms have yet to be analyzed carefully, since platelet growth factors can not be considered as the sole actors triggering this kind of tissue long-term development.

Finally, the role of the fibrin matrix must not be neglected, since it also plays the function of protective barrier and migration matrix [61, 91]. This strong architecture is particularly useful when an open wound is closed using only L-PRF membranes, and the membranes will then serve as a guide for healing, through cell migration and re-epithelialization within the superficial PRF layers, as always observed during tooth avulsion and alveolar sockets regeneration Fig. (3).

7. PRP AND GUIDED BONE REGENERATION (GBR), L-PRF AND NATURAL BONE REGENERATION (NBR)

7.1. PRP Gels, Bone Graft and GBR

The ultimate clinical situation where PRP gels or PRF could be useful during periodontal surgery, is after teeth avulsion when the alveolar ridges require a significant regeneration in order to rebuild the hard and soft tissue potential before implant placement. One every important approach is an evolution of GTR, and is called Guided Bone Regeneration (GBR).

The concept of Guided Bone Regeneration is to regenerate a bone volume through the protection of the blood clot within the bone compartment under a resorbable (collagen,...) or non resorbable (ePTFE,...) membrane. The original version of GBR only requires the filling of the bone cavities with a natural blood clot, but this bone compartment is most times also filled with a bone material (autologous, allograft, xenograft or synthetic) and then protected using the membranes. The limit between GBR and a bone graft can sometimes be very thin. But the principles of GBR are also very similar to GTR, the main difference being that GBR is supposed to regenerate bone after tooth avulsion in order to preserve a significant tissue volume for further implant placement, while GTR has to regenerate the ligament and all the other periodontal tissues around a periodontally compromised tooth. By extension, the term GBR can be used in other circumstances where bone regeneration is required, such as the regeneration of bone around compromised osseointegrated implants [158, 159] or the regeneration of a toothless damaged alveolar ridge [160, 161].

The use of PRP gels in GBR logically presents the same advantages and inconvenients than their use during GTR, and is the natural evolution of the use of PRP gels in dental avulsion and gingival surgery. If these gels could improve alveolar sockets regeneration and soft tissue healing, they seemed the perfect adjuvant during GBR in order to increase the natural blood clot stability or to stimulate bone healing below the GBR membrane, and to increase soft tissue healing above the membrane. Indeed, the main problem with GBR is the wound closure, since delayed soft tissue healing is often encountered above the membranes, resulting in poor soft tissue resistance, gingival dehiscence (and even necrosis) with contamination of the membrane below and finally bacterial contamination of the regeneration compartment with severe risk of necrosis. Logically, a surgical adjuvant that could limit the risk of flap necrosis or gingival dehiscence would be a very welcome addition to the technique.

Unfortunately, once again the results are quite contradictory. Several authors showed that a combination of PRP gels with a bone substitute (anorganic bovine bone, allograft,...) during GBR gave excellent results [160, 162], while other authors presented mixed results [163]. When the bone quality was assessed in various histological models, authors did not pointed out significant differences in terms of bone remodelling with or without PRPs [159, 161]. These results finally reveal the biggest interrogation regarding PRP gels: do PRP gels truly improve bone healing and long-term remodelling ? This question goes far beyond the GBR application, and is in fact the key issue in many maxillofacial applications, particularly dental implant surgery and bone graft for reconstructive surgery.

7.2. L-PRF, Bone Graft and NBR

The use of L-PRF membranes during the treatment of periodontal intrabony defects was called NTR and represented an alternative technique to GTR. Logically GBR can evolve into a new form of bone regeneration using L-PRF membranes, called Natural Bone Regeneration (NBR).

NBR is based on the same principles than NTR described previously, the main difference being that NBR only targets to regenerate bone (and not the periodontal ligament and gingival attachment on the teeth), and consequently also to regenerate the gingival tissue covering this bone: in the NBR core concept, like in NTR, hard and soft tissues can not be considered separately.

All the problems previously pointed out with GTR membranes are even amplified when these membranes are used in GBR, since the volume and area of regeneration are always much larger in GBR. Non resorbable membranes (such as ePTFE, GoreTex...) are often associated with delayed wound healing and subsequent bacterial contamination, tissue necrosis and regeneration failure. Resorbable membranes are often xenografts (porcine or bovine) and can be refused by the patients ; moreover, they are not mechanically strong enough to protect the bone regenerative compartment, and therefore bone grafting is often required below the membrane to maintain the space and the regenerative morphology ("scaffolding" action). For all these reasons, the original GBR principles of the « blood clot protected below a membrane » have been replaced by intermediary techniques using bone graft, sometimes with the addition of membranes. But these bone grafts present their own limits, particularly in complex cases, when the surgical site is infected and damaged due to inflammation and even sometimes necrosis. The general health status of the patient also interferes with these very sensitive techniques, since all diseases or habits that may reduce the healing potential are contraindications to GBR: for example, strong smoking habits will often lead to clinical disasters. The restrictions of GBR are even more important than the limits of GTR, due to the specific volume and anatomical situation of the regeneration compartments in GBR. However, the best moment for starting a bone and soft tissue regeneration is just after tooth avulsion, when the healing potential is the highest: but this is also the moment where inflammatory reactions, infections and soft tissue retractions are naturally the strongest Fig. (9), and thus the worst mo-

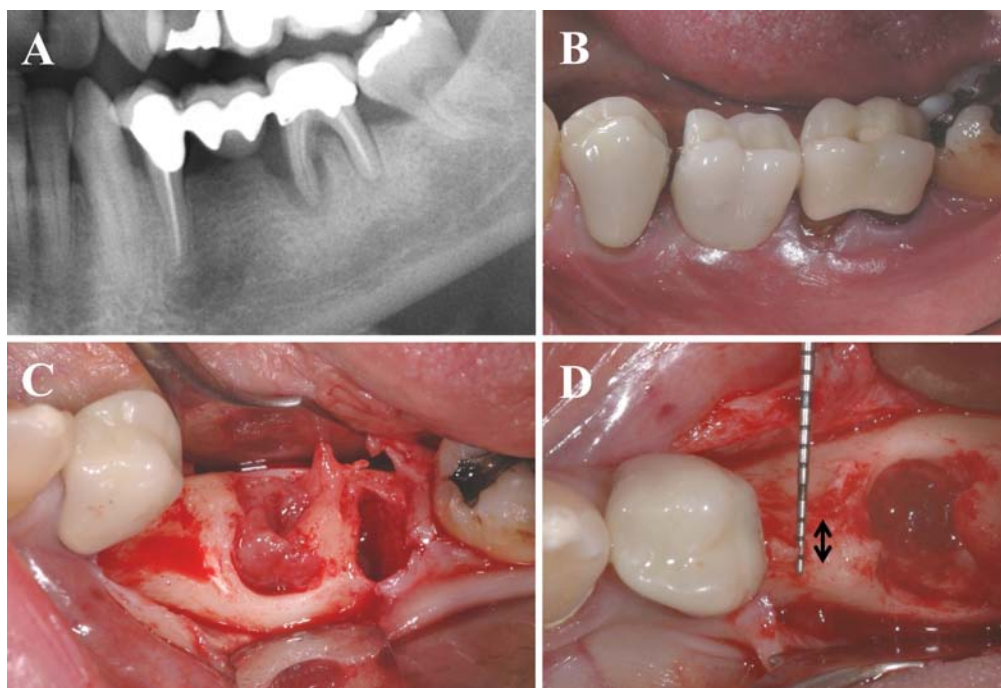


Fig. (9). Natural Bone Regeneration (NBR) in a damaged alveolar ridge. **A.** On the panoramic radiograph, the second left mandibular molar was compromised due to repetitive infections and critical intrabony lesions. This tooth was supporting a bridge that had to be removed during the avulsion of the molar. **B.** Clinical view of the alveolar ridge before tooth avulsion. The bridge was cut carefully. Note that the gingival tissue around the molar was weak, with a very limited height of attached gingiva. **C.** After tooth avulsion, the bone defect was full of fibrous tissues that had to be eliminated. **D.** The cleaned avulsion sockets were large and their regeneration was very important for the placement of implants in good conditions. Moreover, the alveolar ridge ahead of the alveolar socket was quite resorbed, with a residual bone thickness inferior to 3mm (black arrows): the horizontal regeneration of the ridge was also required for an adequate implant placement.

ment for GBR. The concept of NBR is to regenerate these tissues using the amplification of the natural healing, whatever the initial clinical situation. This approach became possible by the use of L-PRF membranes.

The concept of NBR is to promote the regeneration of a bone volume and the gingival tissue above through the use of L-PRF membranes as filling materials within the bone regenerative chamber, most times in association with a bone biomaterials used as space maintainer, and also as protection membrane above the regenerative compartment. This approach is based on the intrinsic polyvalent properties of the L-PRF membranes, since they strongly stimulate proliferation and differentiation of many different kinds of cells, particularly epithelial cells, gingival fibroblasts, osteoblasts and bone mesenchymal stem cells [91, 92]. The membranes can thus be used in both bone and gingival compartments. The NBR is often combined with a metronidazole solution soaking the filling material in order to protect the bone healing compartment from the unavoidable bacterial contaminations [144]. The biological mechanisms defining the NBR are however much more complex than a simple stimulation through growth factor release.

First, within the bone regenerative compartment, the L-PRF plays the same role as the natural blood clot used in GBR under the membrane, the main difference being that the L-PRF clot is much more stable. Like the natural blood clot, the L-PRF matrix is a soft material and therefore the bone regenerative chambers have to be protected from mechanical constraints and crushing: the simplest method is to mix the

L-PRF with a bone material in order to fill the bone chamber with a denser filling conglomerate [54, 55]. The introduction of a bone material however raised the complex question of the adequate material to associate with L-PRF: excellent results were obtained with collagenated allografts and xenografts Figs. (9 and 10), but this aspect should be analyzed in more details in the future.

Second, the key principle of NBR is to protect the bone regenerative compartment with L-PRF membranes only, and to avoid the use of GBR membranes: the problems of flap necrosis, soft tissue dehiscence and contamination encountered in GBR are thus logically reduced. The L-PRF membranes must not be considered as an adjuvant to a classical GBR procedure, but must be used as the main tool of the bone and soft tissue regenerative procedure. Some authors tried indeed to use PRF membranes below and above non resorbable titanium GBR membranes, in order to fill infected alveolar sockets, improve soft tissue healing and avoid flap necrosis: this first application gave good clinical results, but soft tissue dehiscences were encountered [164]. This result shows that PRF membranes could for sure improve the classical GBR procedures (particularly in infected or inflammatory sites), but the advantages are limited. On the contrary, the NBR requires to think different the role of the protection membrane.

Indeed, the NBR concept must be considered as an independent approach from GBR. The L-PRF membranes do not only improve soft tissue neoangiogenesis and wound closure, they also play the function of competitive barrier be-

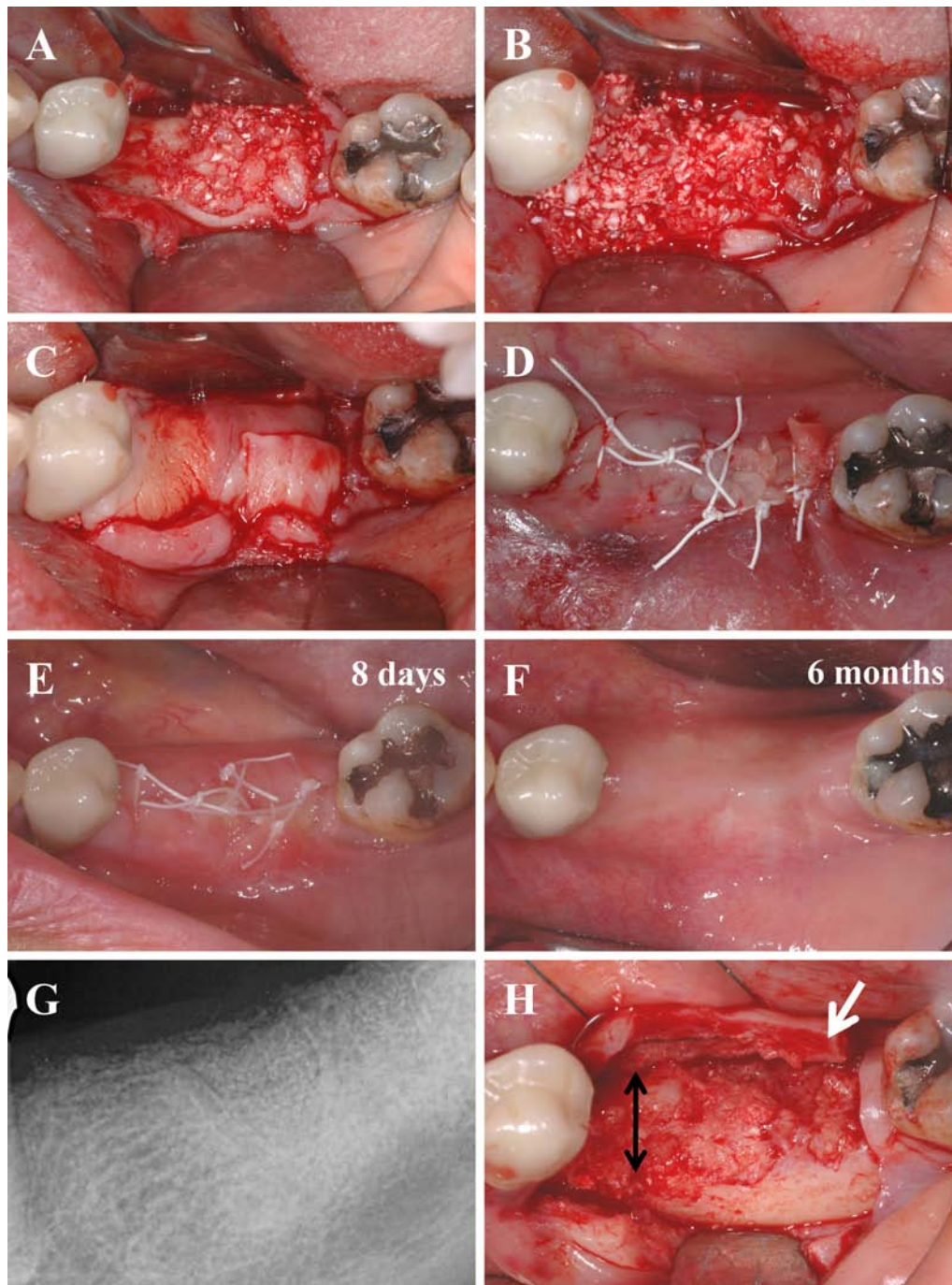


Fig. (10). Natural Bone Regeneration (NBR) in a damaged alveolar ridge. **A.** The avulsion sockets were filled with a mix of L-PRF and xenogeneic collagenated bone (Gen-Os, OsteoBiol, Tecnos, Italy) in a 50/50 volumic ratio, in association with a 0.5% metronidazole solution. **B.** The same bone/L-PRF mix was then grafted all over the resorbed residual alveolar ridge ahead of the avulsion socket. **C.** Four L-PRF membranes were then used to cover the whole bone regenerative compartment. **D.** Deep sutures were performed. Because of the grafted volume, an excessive traction of the flap would have been required for a complete closure of the surgical site: in order to keep the gingival flap in an apical natural position, the vestibular and lingual flaps were not sutured edge to edge. The external L-PRF layer remained partially in contact with the oral cavity. **E.** Eight days after the surgery, the induction phase was almost finished, the gingival tissue was still highly proliferative and starting the merging phase between the gingival connective tissue and the L-PRF layers. The swollen aspect due to the bone graft and the thick layer of L-PRF had considerably diminished. Note that postsurgical pain and edema were minimal. **F.** Six months after the surgery, the alveolar ridge seemed correctly healed. The gingiva was thick and homogeneous. **G.** A retroalveolar radiograph confirmed the complete filling of the bone defects. The radiologic bone density seemed homogeneous on the whole area, the previous bone defects were no more detectable after 6 months. **H.** During the implant placement, the regenerated alveolar ridge was reopened and checked. The attached gingival tissue was very thick (white arrow) and the narrow alveolar crest became a thick bone ridge with more than 5mm in thickness (black arrows). The regenerated area was perfect for esthetic and functional implant placement.

tween the bone and gingival compartments. As an optimized blood clot, the L-PRF membrane uses a completely different biological mechanism than the cell-proof barriers used in GBR [145]. In NBR, the function of competitive barrier attributed to the L-PRF covering membranes is a key principle of the clinical success. Indeed, the stimulation of the periosteum is the best way for the regeneration of the bone chamber, the reinforcement of the gingival tissue covering the site, and also to avoid the invagination of the soft tissue inside the bone chamber. The stimulation of the periosteum simply creates the new stable bone/gingiva border, blocks any territorial conflicts between the tissues by their mutual reinforcement and exchanges through the neoperiosteum. While GBR membranes act as a foreign body to block the interactions and migration (particularly the neoangiogenesis) between the 2 compartments – the bone chamber and the gingival cover – and therefore promote the associated risks of delayed healing and necrosis, the NBR membrane must naturally reinforce the border between the 2 compartments and stimulate their mutual exchanges and synchronized regeneration. This is the concept of competitive barrier already developed for NTR: the L-PRF membrane is not cell-proof and on the contrary stimulates the proliferation and differentiation of cells within the fibrin membrane. The membrane therefore becomes the new interface between the bone and gingival compartments and stimulates both tissues and the growth of their new periosteal barrier. This concept of competitive barrier was already important in NTR, as explained in a precedent chapter, it becomes even critical in GBR where the size of the regeneration chambers are much larger.

Third, the impact of the L-PRF cover on the soft tissue healing and remodelling is also a key parameter of the NBR concept. The phenomenon of induction previously explained is necessary for the reinforcement of the gingival cover and thus the long-term success of the global regeneration. This is another main difference with GBR, where the gingival regeneration was always secondary: in NBR, the regeneration of the bone and gingival compartments is synchronized. This induction on the gingival tissue is related to the slow release of growth factors and other matrix proteins during the whole remodelling of the fibrin layer into a neomatrix, and allows to reach impressive clinical results, particularly in implant dentistry [54, 55]. However, it is important to keep in mind that the quality of the gingival regeneration is also dependent on the volume and quality of the associated regenerated bone volume supporting the gingiva. Synchronized regeneration is a key principle of NBR, and has to be mastered to reach the best possible results in implant-supported rehabilitation, as it will be discussed in the second part of this article.

The difference between GBR and NBR is thus not only a question of family of membranes, this is a completely different philosophy of surgical treatment: the GBR concept is to guide and force bone and gingiva to heal separately in an artificial way, while the NBR concept is to stimulate the natural healing potential of both tissues and to guide the interlinked development of the bone and gingival compartments along the L-PRF interface.

The NBR technique is based on the use of an optimized blood clot, and it can be used in all kinds of patients (even patients under anticoagulants, smokers, etc.). This approach

can be widely developed in daily practice and in all kinds of clinical situations: infected alveolar sockets, necrosed flaps or bone Fig. (11),... It is for example possible to regenerate hard and soft tissues after a failed GBR that had led to a clinical disaster: necrosed gingival tissue, inflammatory retracted flap, bone sequestra. Following the principles of NBR after the cleaning of such a compromised site, the treatment offers excellent results. Moreover, NBR and NTR are using similar mechanisms and they can thus easily be combined when the bone defect on the alveolar ridge expanded over the close dental roots Fig. (11).

Clinically, the NBR protocol is quite simple: the bone regenerative compartment is filled with L-PRF, most times in association with a bone substitute used as a solid space maintainer and soaked in a 0.5% metronidazole solution, and it is then covered with L-PRF membranes Figs. (9 and 10). These latter function as a protection layer for the bone chamber and trigger the induction of the soft tissue healing and remodelling [54, 55]. As a competitive barrier, this L-PRF layer reinforces the periosteum as a strong interface between the 2 regenerative compartments. However, the L-PRF layer also often plays the function of transitory soft tissue cover. Indeed very often during NBR procedures, the L-PRF membranes remain partially exposed in the oral cavity, since the gingival tissue flaps are too damaged and retracted (or simply too short when the grafted volume is very large) to fully cover the whole surgical site. In these cases, the L-PRF membranes should be used in a thick layer, and serve as a pattern for soft tissue regeneration, through the stimulation and direction of cell migration and proliferation within the fibrin matrix, the development of neoangiogenesis within the membranes and the promotion of the superficial wound re-epithelialization and closure, whatever the initial damage of the flap Fig. (10). However such a successful result requires efficient sutures and expert tissue manipulation from the surgeon.

The NBR protocol gives excellent results in many clinical situations, with only few contraindications and a limited risk of negative effects. The concepts of NBR can be extended to many clinical situations where bone regeneration is required, such as peri-implant bone regeneration [165, 166], sinus lifts [48, 53, 56] or alveolar ridge lateral augmentations [54, 55] Fig. (10). The exact border between bone graft and NBR may sometimes seem difficult to define. Consequently, the optimization of the NBR procedure is highly dependent on the selection of the right bone biomaterial to associate with L-PRF. Excellent results are obtained with various forms of freeze-dried bone allografts and xenografts, but many studies are still required to understand all the associated mechanisms and to select the most adapted bone substitutes for NBR procedures and the adequate way to combine it with L-PRF in the various clinical configurations. The selection of the adequate bone materials is however a very complex subjects, not only for NBR but for all forms of bone regeneration, as it will be developed in the second part of this article.

CONCLUSIONS AND PERSPECTIVES

PRP gels and PRF are innovative tools with many potential applications in periodontal and dentoalveolar surgery.

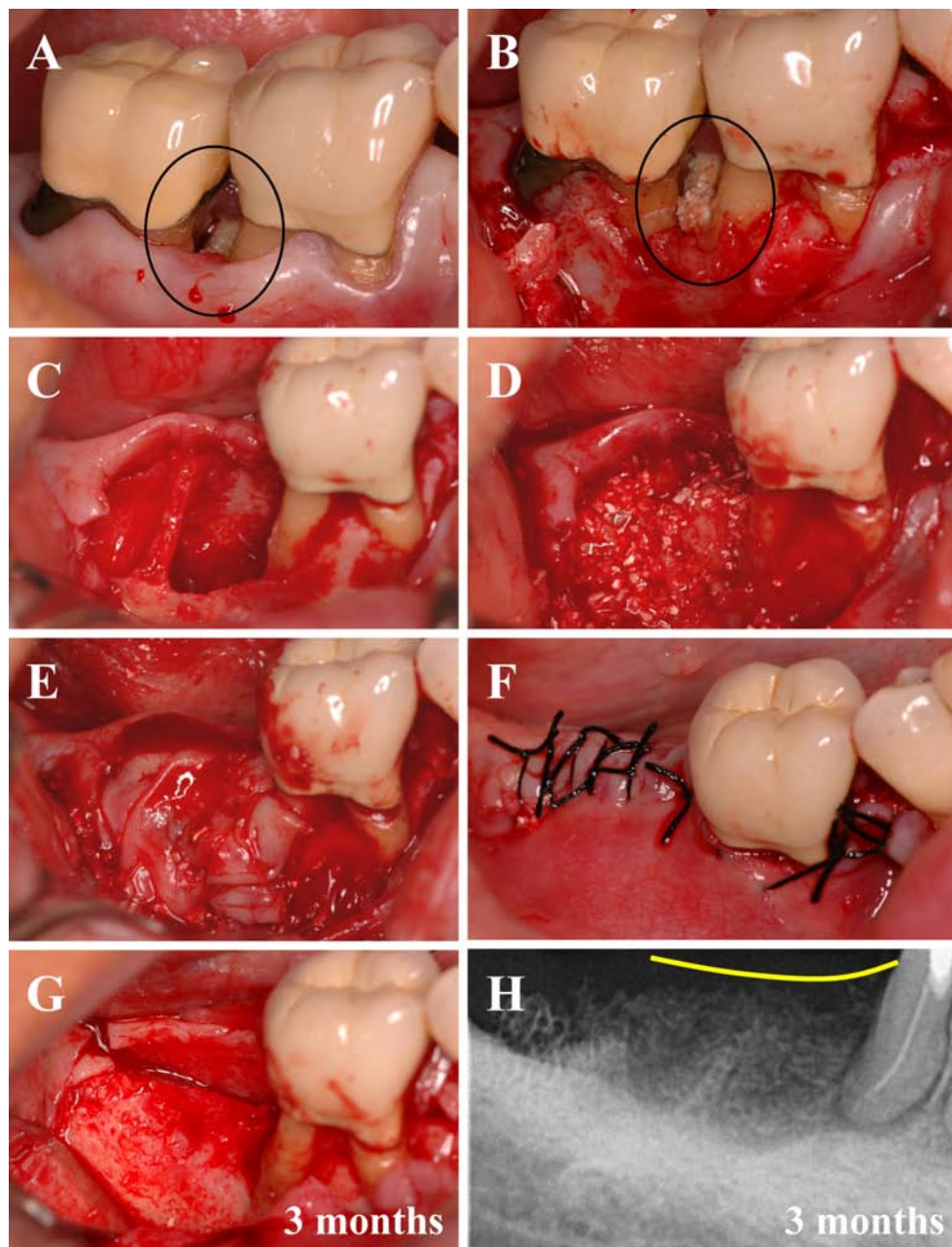


Fig. (11). Combination of Natural Bone Regeneration (NBR) and Natural Tissue Regeneration (NTR) in a damaged alveolar ridge. A and B. The right mandibular first and second molars were compromised by deep intrabony lesions associated with the osteonecrosis of the bone interdental septum (black circle). **C.** The second molar was avulsed and the necrosed bone was carefully curetted, leading to a critical-sized bone defect, extended on the whole distal face (and also partially on the vestibular and lingual faces) of the root of the first molar. This molar was not avulsed but was compromised, since the osteonecrosis had destroyed the periodontal bone support down to the apex. **D.** The extended bone defect was filled with a mix of L-PRF and xenogeneic collagenated bone (Gen-Os, OsteoBiol, Tecness, Italy) in a 50/50 volumic ratio, in association with a 0.5% metronidazole solution. **E.** Bone compartment was covered with 4 L-PRF membranes. Care was taken to envelop with the membranes the grafted area around the distal root of the first molar. **F.** Tight sutures were performed. **G.** Three months later, during the implant placement, the regenerated alveolar ridge was reopened and checked. The regeneration of the bone necrosed area (by NBR) and of the periodontal tissues supporting the compromised first molar (by NTR) seemed optimal. **H.** A retroalveolar radiograph confirmed the complete bone and periodontal regeneration up to an almost natural level (yellow line). Note that after 3 months, the bone compartment was clinically regenerated, but still not completely mineralized since the bone density on the radiograph was still lower in the regenerated area than in the normal bone around.

The literature on the topic is quite confusing, but a careful evaluation of the published data and current clinical experiences on the topic allow to draw 2 main conclusions.

First, we are now living a transition period. PRP gels have lost a significant part of their credibility in oral surgery, while the use of L-PRF membranes only starts his quick

spread. Indeed PRP gels are expensive and time-consuming techniques, that failed to prove their true relevance in daily practice, even if some good clinical results were observed. The contradictory literature about PRP gels in periodontal and dentoalveolar surgery is probably related to the lack of characterization of the tested products and many misunderstandings in the best way to use it. We tried, in this review, to point out some reasons – often very simple and logical – of the contradictory results. PRP gels present interesting results as surgical adjuvant when used correctly (for example during GTR and GBR), but their inconvenients are stronger than their advantages in surgical periodontology. On the contrary, the literature about products from the PRF subfamilies (particularly L-PRF) is only starting to develop, and L-PRF membranes intrinsically fit to periodontal and dentoalveolar applications: user-friendly, easy to prepare and inexpensive, these membranes promote excellent clinical results but also allowed the development of new therapeutic concepts such as NTR and NBR. PRP gels were surgical adjuvants, L-PRF membranes are tissues for regenerative medicine. This new approach may open a new chapter of periodontal surgery.

The second conclusion is that the definition and validation of accurate protocols is a key issue for the long-term development of these techniques. It was true with the various PRP gels, it is also true for the L-PRF membranes. Even if L-PRF membranes are particularly adapted to daily periodontal surgery practice, the relevance of this technique on a long-term basis as a tool of regenerative medicine widely spread in the oral surgeon community is highly dependent on the ability of researchers to accurately define the best indications, to select the adequate kind and quantity of bone materials to combine with the L-PRF, and to validate secure surgical procedures where the concept of NTR and NBR can show their full potential. This aspect will be widely developed in the part 2 of this article.

DISCLOSURE OF INTEREST

The authors declare no competing financial interests.

ACKNOWLEDGEMENTS

This work was supported by the LoB5 Foundation for Research, Paris, France.

REFERENCES

- [1] Dohan Ehrenfest, D.M.; Rasmusson, L.; Albrektsson, T. Classification of platelet concentrates: from pure platelet-rich plasma (P-PRP) to leucocyte- and platelet-rich fibrin (L-PRF). *Trends Biotechnol.*, **2009**, *27*(3), 158-167.
- [2] Whitman, D.H.; Berry, R.L.; Green, D.M. Platelet gel: an autologous alternative to fibrin glue with applications in oral and maxillofacial surgery. *J. Oral Maxillofac. Surg.*, **1997**, *55*(11), 1294-1299.
- [3] Marx, R.E.; Carlson, E.R.; Eichstaedt, R.M.; Schimmele, S.R.; Strauss, J.E.; Georgeff, K.R. Platelet-rich plasma: Growth factor enhancement for bone grafts. *Oral Surg. Oral Med. Oral Pathol. Oral Radiol. Endod.*, **1998**, *85*(6), 638-646.
- [4] Matras, H. Die Wirkungen verschiedener fibrinpräparate auf kontinuierlich-strengungen der rattenhaut. *Osterr. Z. Stomatol.*, **1970**, *67*(9), 338-359.
- [5] Matras, H. The use of fibrin sealant in oral and maxillofacial surgery. *J. Oral Maxillofac. Surg.*, **1982**, *40*(10), 617-622.
- [6] Gibble, J.W.; Ness, P.M. Fibrin glue: the perfect operative sealant? *Transfusion*, **1990**, *30*(8), 741-747.
- [7] Rosenthal, A.R.; Egbert, P.R.; Harbury, C.; Hopkins, J.L.; Rubenstein, E. Use of platelet-fibrinogen-thrombin mixture to seal experimental penetrating corneal wounds. *Albrecht Von Graefes Arch. Klin. Exp. Ophthalmol.*, **1978**, *207*(2), 111-115.
- [8] Rosenthal, A.R.; Harbury, C.; Egbert, P.R.; Rubenstein, E. Use of a platelet-fibrinogen-thrombin mixture as a corneal adhesive: experiments with sutureless lamellar keratoplasty in the rabbit. *Invest. Ophthalmol.*, **1975**, *14*(11), 872-875.
- [9] Silverberg, G.D.; Harbury, C.B.; Rubenstein, E. A physiological sealant for cerebrospinal fluid leaks. *J. Neurosurg.*, **1977**, *46*(2), 215-219.
- [10] Pearl, R.M.; Wustrack, K.O.; Harbury, C.; Rubenstein, E.; Kaplan, E.N. Microvascular anastomosis using a blood product sealant-adhesive. *Surg. Gynecol. Obstet.*, **1977**, *144*(2), 227-231.
- [11] Tayapongsak, P.; O'Brien, D.A.; Monteiro, C.B.; Arceo-Diaz, L.Y. Autologous fibrin adhesive in mandibular reconstruction with particulate cancellous bone and marrow. *J. Oral Maxillofac. Surg.*, **1994**, *52*(2), 161-165.
- [12] Knighton, D.R.; Ciresi, K.; Fiegel, V.D.; Schumert, S.; Butler, E.; Cerra, F. Stimulation of repair in chronic, nonhealing, cutaneous ulcers using platelet-derived wound healing formula. *Surg. Gynecol. Obstet.*, **1990**, *170*(1), 56-60.
- [13] Knighton, D.R.; Ciresi, K.F.; Fiegel, V.D.; Austin, L.L.; Butler, E.L. Classification and treatment of chronic nonhealing wounds. Successful treatment with autologous platelet-derived wound healing factors (PDWHF). *Ann. Surg.*, **1986**, *204*(3), 322-330.
- [14] Knighton, D.R.; Doucette, M.; Fiegel, V.D.; Ciresi, K.; Butler, E.; Austin, L. The use of platelet derived wound healing formula in human clinical trials. *Prog. Clin. Biol. Res.*, **1988**, *266*, 319-329.
- [15] Dohan Ehrenfest, D.M.; Bielecki, T.; Del Corso, M.; Inchingolo, F.; Sammartino, G. Shedding light in the controversial terminology for platelet-rich products: platelet-rich plasma (PRP), platelet-rich fibrin (PRF), platelet-leukocyte gel (PLG), preparation rich in growth factors (PRGF), classification and commercialism. *J. Biomed. Mater. Res. A*, **2010**, *95*(4), 1280-1282.
- [16] Weibrich, G.; Kleis, W.K. Curasan PRP kit vs. PCCS PRP system. Collection efficiency and platelet counts of two different methods for the preparation of platelet-rich plasma. *Clin. Oral Implants Res.*, **2002**, *13*(4), 437-443.
- [17] Weibrich, G.; Kleis, W.K.; Buch, R.; Hitzler, W.E.; Hafner, G. The Harvest Smart PRePTM system versus the Friadent-Schutze platelet-rich plasma kit. *Clin. Oral Implants Res.*, **2003**, *14*(2), 233-239.
- [18] Weibrich, G.; Kleis, W.K.; Hafner, G. Growth factor levels in the platelet-rich plasma produced by 2 different methods: curasan-type PRP kit versus PCCS PRP system. *Int. J. Oral Maxillofac. Implants*, **2002**, *17*(2), 184-190.
- [19] Weibrich, G.; Kleis, W.K.; Hafner, G.; Hitzler, W.E.; Wagner, W. Comparison of platelet, leukocyte, and growth factor levels in point-of-care platelet-enriched plasma, prepared using a modified Curasan kit, with preparations received from a local blood bank. *Clin. Oral Implants Res.*, **2003**, *14*(3), 357-362.
- [20] Weibrich, G.; Kleis, W.K.; Hitzler, W.E.; Hafner, G. Comparison of the platelet concentrate collection system with the plasma-rich-in-growth-factors kit to produce platelet-rich plasma: a technical report. *Int. J. Oral Maxillofac. Implants*, **2005**, *20*(1), 118-123.
- [21] Weibrich, G.; Kleis, W.K.; Kunz-Kostomanolakis, M.; Loos, A.H.; Wagner, W. Correlation of platelet concentration in platelet-rich plasma to the extraction method, age, sex, and platelet count of the donor. *Int. J. Oral Maxillofac. Implants*, **2001**, *16*(5), 693-699.
- [22] Dohan Ehrenfest, D.M.; Del Corso, M.; Diss, A.; Mouhyi, J.; Charrier, J.B. Three-dimensional architecture and cell composition of a choukroun's platelet-rich fibrin clot and membrane. *J. Periodontol.*, **2010**, *81*(4), 546-555.
- [23] Fernandez-Barbero, J.E.; Galindo-Moreno, P.; Avila-Ortiz, G.; Caba, O.; Sanchez-Fernandez, E.; Wang, H.L. Flow cytometric and morphological characterization of platelet-rich plasma gel. *Clin. Oral Implants Res.*, **2006**, *17*(6), 687-693.
- [24] Mazzucco, L.; Balbo, V.; Cattana, E.; Guaschino, R.; Borzini, P. Not every PRP-gel is born equal. Evaluation of growth factor availability for tissues through four PRP-gel preparations: Fibrinet, regenprp-kit, plateltext and one manual procedure. *Vox Sang.*, **2009**, *97*(2), 110-118.
- [25] Mosesson, M.W.; Siebenlist, K.R.; Meh, D.A. The structure and biological features of fibrinogen and fibrin. *Ann. N.Y. Acad. Sci.*, **2001**, *936*, 11-30.
- [26] Bielecki, T.; Gazdzik, T.S.; Szczepanski, T. Re: "The effects of local platelet rich plasma delivery on diabetic fracture healing". What do we use: Platelet-rich plasma or platelet-rich gel? *Bone*, **2006**, *39*(6), 1388.

- [27] Everts, P.A.; van Zundert, A.; Schonberger, J.P.; Devilee, R.J.; Knape, J.T. What do we use: Platelet-rich plasma or platelet-leukocyte gel? *J. Biomed. Mater. Res. A*, **2008**, *85*(4), 1135-1136.
- [28] Bielecki, T.; Gazdzik, T.S.; Szczepanski, T. Benefit of percutaneous injection of autologous platelet-leukocyte-rich gel in patients with delayed union and nonunion. *Eur. Surg. Res.*, **2008**, *40*(3), 289-296.
- [29] Bielecki, T.M.; Gazdzik, T.S.; Arendt, J.; Szczepanski, T.; Krol, W.; Wielkoszynski, T. Antibacterial effect of autologous platelet gel enriched with growth factors and other active substances: an *in vitro* study. *J. Bone Joint Surg. Br.*, **2007**, *89*(3), 417-420.
- [30] Cieslik-Bielecka, A.; Bielecki, T.; Gazdzik, T.S.; Arendt, J.; Krol, W.; Szczepanski, T. Autologous platelets and leukocytes can improve healing of infected high-energy soft tissue injury. *Transfus. Apher. Sci.*, **2009**, *41*(1), 9-12.
- [31] Cieslik-Bielecka, A.; Gazdzik, T.S.; Bielecki, T.M.; Cieslik, T. Why the platelet-rich gel has antimicrobial activity? *Oral Surg. Oral Med. Oral Pathol. Oral Radiol. Endod.*, **2007**, *103*(3), 303-305.
- [32] El-Sharkawy, H.; Kantarci, A.; Deady, J.; Hasturk, H.; Liu, H.; Alshahat, M.; Van Dyke, T.E. Platelet-rich plasma: growth factors and pro- and anti-inflammatory properties. *J. Periodontol.*, **2007**, *78*(4), 661-669.
- [33] Everts, P.A.; Devilee, R.J.; Brown Mahoney, C.; van Erp, A.; Oosterbos, C.J.; Stellenboom, M.; Knape, J.T.; van Zundert, A. Exogenous application of platelet-leukocyte gel during open subacromial decompression contributes to improved patient outcome. A prospective randomized double-blind study. *Eur. Surg. Res.*, **2008**, *40*(2), 203-210.
- [34] Everts, P.A.; Hoffmann, J.; Weibrich, G.; Mahoney, C.B.; Schonberger, J.P.; van Zundert, A.; Knape, J.T. Differences in platelet growth factor release and leukocyte kinetics during autologous platelet gel formation. *Transfus. Med.*, **2006**, *16*(5), 363-368.
- [35] Everts, P.A.; Overdeest, E.P.; Jakimowicz, J.J.; Oosterbos, C.J.; Schonberger, J.P.; Knape, J.T.; van Zundert, A. The use of autologous platelet-leukocyte gels to enhance the healing process in surgery, a review. *Surg. Endosc.*, **2007**, *21*(11), 2063-2068.
- [36] Moojen, D.J.; Everts, P.A.; Schure, R.M.; Overdeest, E.P.; van Zundert, A.; Knape, J.T.; Castelein, R.M.; Creemers, L.B.; Dhert, W.J. Antimicrobial activity of platelet-leukocyte gel against *Staphylococcus aureus*. *J. Orthop. Res.*, **2008**, *26*(3), 404-410.
- [37] Mishra, A.; Pavelko, T. Treatment of chronic elbow tendinosis with buffered platelet-rich plasma. *Am. J. Sports Med.*, **2006**, *34*(11), 1774-1778.
- [38] Mishra, A.; Woodall, J. Jr.; Vieira, A. Treatment of tendon and muscle using platelet-rich plasma. *Clin. Sports Med.*, **2009**, *28*(1), 113-125.
- [39] Clark, R.A. Fibrin and wound healing. *Ann. N.Y. Acad. Sci.*, **2001**, *936*, 355-367.
- [40] van Hinsbergh, V.W.; Collen, A.; Koolwijk, P. Role of fibrin matrix in angiogenesis. *Ann. N.Y. Acad. Sci.*, **2001**, *936*, 426-437.
- [41] Martin, P.; Leibovich, S.J. Inflammatory cells during wound repair: the good, the bad and the ugly. *Trends Cell Biol.*, **2005**, *15*(11), 599-607.
- [42] Dohan Ehrenfest, D.M.; Lemo, N.; Jimbo, R.; Sammartino, G. Selecting a relevant animal model for testing the *in vivo* effects of Choukroun's platelet-rich fibrin (PRF): Rabbit tricks and traps. *Oral Surg. Oral Med. Oral Pathol. Oral Radiol. Endod.*, **2010**, *110*(4), 413-416.
- [43] Simon, B.I.; Zatzoff, A.L.; Kong, J.J.; O'Connell, S.M. Clinical and histological comparison of extraction socket healing following the use of autologous platelet-rich fibrin matrix (PRFM) to ridge preservation procedures employing demineralized freeze dried bone allograft material and membrane. *Open Dent. J.*, **2009**, *3*, 92-99.
- [44] Dohan, D.M.; Choukroun, J.; Diss, A.; Dohan, S.L.; Dohan, A.J.; Mouhyi, J.; Gogly, B. Platelet-rich fibrin (PRF): a second-generation platelet concentrate. Part I: technological concepts and evolution. *Oral Surg. Oral Med. Oral Pathol. Oral Radiol. Endod.*, **2006**, *101*(3), e37-44.
- [45] Dohan, D.M.; Choukroun, J.; Diss, A.; Dohan, S.L.; Dohan, A.J.; Mouhyi, J.; Gogly, B. Platelet-rich fibrin (PRF): a second-generation platelet concentrate. Part II: platelet-related biologic features. *Oral Surg. Oral Med. Oral Pathol. Oral Radiol. Endod.*, **2006**, *101*(3), e45-50.
- [46] Dohan, D.M.; Choukroun, J.; Diss, A.; Dohan, S.L.; Dohan, A.J.; Mouhyi, J.; Gogly, B. Platelet-rich fibrin (PRF): a second-generation platelet concentrate. Part III: leucocyte activation: a new feature for platelet concentrates? *Oral Surg. Oral Med. Oral Pathol. Oral Radiol. Endod.*, **2006**, *101*(3), e51-55.
- [47] Choukroun, J.; Diss, A.; Simonpieri, A.; Girard, M.O.; Schoeffler, C.; Dohan, S.L.; Dohan, A.J.; Mouhyi, J.; Dohan, D.M. Platelet-rich fibrin (PRF): a second-generation platelet concentrate. Part IV: clinical effects on tissue healing. *Oral Surg. Oral Med. Oral Pathol. Oral Radiol. Endod.*, **2006**, *101*(3), e56-60.
- [48] Choukroun, J.; Diss, A.; Simonpieri, A.; Girard, M.O.; Schoeffler, C.; Dohan, S.L.; Dohan, A.J.; Mouhyi, J.; Dohan, D.M. Platelet-rich fibrin (PRF): a second-generation platelet concentrate. Part V: Histologic evaluations of PRF effects on bone allograft maturation in sinus lift. *Oral Surg. Oral Med. Oral Pathol. Oral Radiol. Endod.*, **2006**, *101*(3), 299-303.
- [49] Diss, A.; Dohan, D.M.; Mouhyi, J.; Mahler, P. Osteotome sinus floor elevation using Choukroun's platelet-rich fibrin as grafting material: a 1-year prospective pilot study with microthreaded implants. *Oral Surg. Oral Med. Oral Pathol. Oral Radiol. Endod.*, **2008**, *105*(5), 572-579.
- [50] Jang, E.S.; Park, J.W.; Kweon, H.; Lee, K.G.; Kang, S.W.; Baek, D.H.; Choi, J.Y.; Kim, S.G. Restoration of peri-implant defects in immediate implant installations by Choukroun platelet-rich fibrin and silk fibroin powder combination graft. *Oral Surg. Oral Med. Oral Pathol. Oral Radiol. Endod.*, **2010**, *109*(6), 831-836.
- [51] Lee, E.H.; Kim, J.Y.; Kweon, H.Y.; Jo, Y.Y.; Min, S.K.; Park, Y.W.; Choi, J.Y.; Kim, S.G. A combination graft of low-molecular-weight silk fibroin with Choukroun platelet-rich fibrin for rabbit calvarial defect. *Oral Surg. Oral Med. Oral Pathol. Oral Radiol. Endod.*, **2010**, *109*(5), e33-38.
- [52] Charrier, J.B.; Monteil, J.P.; Albert, S.; Collon, S.; Bobin, S.; Dohan Ehrenfest, D.M. Relevance of Choukroun's platelet-rich fibrin (PRF) and SMAS flap in primary reconstruction after superficial or subtotal parotidectomy in patients with focal pleiomorphic adenoma: a new technique. *Rev. Laryngol. Otol. Rhinol. (Bord.)*, **2008**, *129*(4-5), 313-318.
- [53] Mazar, Z.; Horowitz, R.A.; Del Corso, M.; Prasad, H.S.; Rohrer, M.D.; Dohan Ehrenfest, D.M. Sinus floor augmentation with simultaneous implant placement using Choukroun's platelet-rich fibrin as the sole grafting material: a radiologic and histologic study at 6 months. *J. Periodontol.*, **2009**, *80*(12), 2056-2064.
- [54] Simonpieri, A.; Del Corso, M.; Sammartino, G.; Dohan Ehrenfest, D.M. The relevance of Choukroun's platelet-rich fibrin and metronidazole during complex maxillary rehabilitations using bone allograft. Part I: a new grafting protocol. *Implant Dent.*, **2009**, *18*(2), 102-111.
- [55] Simonpieri, A.; Del Corso, M.; Sammartino, G.; Dohan Ehrenfest, D.M. The relevance of Choukroun's platelet-rich fibrin and metronidazole during complex maxillary rehabilitations using bone allograft. Part II: implant surgery, prosthodontics, and survival. *Implant Dent.*, **2009**, *18*(3), 220-229.
- [56] Simonpieri, A.; Choukroun, J.; Del Corso, M.; Sammartino, G.; Dohan Ehrenfest, D.M. Simultaneous sinus-lift and implantation using microthreaded implants and leukocyte- and platelet-rich fibrin as sole grafting material: a six-year experience. *Implant Dent.*, **2011**, *20*(1), 2-12.
- [57] Braccini, F.; Dohan, D.M. The relevance of Choukroun's platelet rich fibrin (PRF) during facial aesthetic liposuction (Coleman's technique): preliminary results. *Rev. Laryngol. Otol. Rhinol. (Bord.)*, **2007**, *128*(4), 255-260.
- [58] Braccini, F.; Tardivet, L.; Dohan Ehrenfest, D.M. The relevance of Choukroun's platelet-rich fibrin (PRF) during middle ear surgery: preliminary results. *Rev. Laryngol. Otol. Rhinol. (Bord.)*, **2009**, *130*(3), 175-180.
- [59] Choukroun, J.I.; Braccini, F.; Diss, A.; Giordano, G.; Doglioli, P.; Dohan, D.M. Influence of platelet rich fibrin (PRF) on proliferation of human preadipocytes and tymanic keratinocytes: A new opportunity in facial liposuction (Coleman's technique) and tymanoplasty? *Rev. Laryngol. Otol. Rhinol. (Bord.)*, **2007**, *128*(1-2), 27-32.
- [60] Man, D.; Plosker, H.; Winland-Brown, J.E. The use of autologous platelet-rich plasma (platelet gel) and autologous platelet-poor plasma (fibrin glue) in cosmetic surgery. *Plast. Reconstr. Surg.*, **2001**, *107*(1), 229-237.
- [61] Del Corso, M.; Sammartino, G.; Dohan Ehrenfest, D.M. Re: "Clinical evaluation of a modified coronally advanced flap alone or in combination with a platelet-rich fibrin membrane for the treatment of adjacent multiple gingival recessions: a 6-month study". *J. Periodontol.*, **2009**, *80*(11), 1694-1697.

- [62] Dohan Ehrenfest, D.M.; Del Corso, M.; Inchingolo, F.; Sammartino, G.; Charrier, J.B. Platelet-rich plasma (PRP) and platelet-rich fibrin (PRF) in human cell cultures: growth factor release and contradictory results. *Oral Surg. Oral Med. Oral Pathol. Oral Radiol. Endod.*, **2010**, *110*(4), 418-421.
- [63] Dohan Ehrenfest, D.M.; Del Corso, M.; Inchingolo, F.; Charrier, J.B. Selecting a relevant *in vitro* cell model for testing and comparing the effects of a Choukroun's platelet-rich fibrin (PRF) membrane and a Platelet-Rich Plasma (PRP) gel: tricks and traps. *Oral Surg. Oral Med. Oral Pathol. Oral Radiol. Endod.*, **2010**, *110*(4), 409-411.
- [64] Celotti, F.; Colciago, A.; Negri-Cesi, P.; Pravettoni, A.; Zaninetti, R.; Sacchi, M.C. Effect of platelet-rich plasma on migration and proliferation of SaOS-2 osteoblasts: role of platelet-derived growth factor and transforming growth factor-beta. *Wound Repair Regen.*, **2006**, *14*(2), 195-202.
- [65] Arpornmaeklong, P.; Kochel, M.; Depprich, R.; Kubler, N.R.; Wurzler, K.K. Influence of platelet-rich plasma (PRP) on osteogenic differentiation of rat bone marrow stromal cells. An *in vitro* study. *Int. J. Oral Maxillofac. Surg.*, **2004**, *33*(1), 60-70.
- [66] Ferreira, C.F.; Carriel Gomes, M.C.; Filho, J.S.; Granjeiro, J.M.; Oliveira Simoes, C.M.; Magini Rde, S. Platelet-rich plasma influence on human osteoblasts growth. *Clin. Oral Implants Res.*, **2005**, *16*(4), 456-460.
- [67] Kanno, T.; Takahashi, T.; Tsujisawa, T.; Ariyoshi, W.; Nishihara, T. Platelet-rich plasma enhances human osteoblast-like cell proliferation and differentiation. *J. Oral Maxillofac. Surg.*, **2005**, *63*(3), 362-369.
- [68] Ogino, Y.; Ayukawa, Y.; Kukita, T.; Koyano, K. The contribution of platelet-derived growth factor, transforming growth factor-beta1, and insulin-like growth factor-I in platelet-rich plasma to the proliferation of osteoblast-like cells. *Oral Surg. Oral Med. Oral Pathol. Oral Radiol. Endod.*, **2006**, *101*(6), 724-729.
- [69] Uggeri, J.; Belletti, S.; Guizzardi, S.; Poli, T.; Cantarelli, S.; Scandroglio, R.; Gatti, R. Dose-dependent effects of platelet gel release on activities of human osteoblasts. *J. Periodontol.*, **2007**, *78*(10), 1985-1991.
- [70] Akeda, K.; An, H.S.; Okuma, M.; Attawia, M.; Miyamoto, K.; Thonar, E.J.; Lenz, M.E.; Sah, R.L.; Masuda, K. Platelet-rich plasma stimulates porcine articular chondrocyte proliferation and matrix biosynthesis. *Osteoarthritis Cartilage*, **2006**, *14*(12), 1272-1280.
- [71] Annunziata, M.; Oliva, A.; Buonaiuto, C.; Di Feo, A.; Di Pasquale, R.; Passaro, I.; Guida, L. *In vitro* cell-type specific biological response of human periodontally related cells to platelet-rich plasma. *J. Periodontol. Res.*, **2005**, *40*(6), 489-495.
- [72] Han, J.; Meng, H.X.; Tang, J.M.; Li, S.L.; Tang, Y.; Chen, Z.B. The effect of different platelet-rich plasma concentrations on proliferation and differentiation of human periodontal ligament cells *in vitro*. *Cell Prolif.*, **2007**, *40*(2), 241-252.
- [73] Krasna, M.; Domanovic, D.; Tomsic, A.; Svajger, U.; Jeras, M. Platelet gel stimulates proliferation of human dermal fibroblasts *in vitro*. *Acta Dermatovenerol. Alp. Panonica Adriat.*, **2007**, *16*(3), 105-110.
- [74] Liu, Y.; Kalen, A.; Risto, O.; Wahlstrom, O. Fibroblast proliferation due to exposure to a platelet concentrate *in vitro* is pH dependent. *Wound Repair Regen.*, **2002**, *10*(5), 336-340.
- [75] Bertrand-Duchesne, M.P.; Grenier, D.; Gagnon, G. Epidermal growth factor released from platelet-rich plasma promotes endothelial cell proliferation *in vitro*. *J. Periodontol. Res.*, **2010**, *45*(1), 87-93.
- [76] Doucet, C.; Ernou, I.; Zhang, Y.; Llense, J.R.; Begot, L.; Holy, X.; Lataillade, J.J. Platelet lysates promote mesenchymal stem cell expansion: a safety substitute for animal serum in cell-based therapy applications. *J. Cell Physiol.*, **2005**, *205*(2), 228-236.
- [77] Cenni, E.; Ciapetti, G.; Pagani, S.; Perut, F.; Giunti, A.; Baldini, N. Effects of activated platelet concentrates on human primary cultures of fibroblasts and osteoblasts. *J. Periodontol.*, **2005**, *76*(3), 323-328.
- [78] Slapnicka, J.; Fassmann, A.; Strasak, L.; Augustin, P.; Vanek, J. Effects of activated and nonactivated platelet-rich plasma on proliferation of human osteoblasts *in vitro*. *J. Oral Maxillofac. Surg.*, **2008**, *66*(2), 297-301.
- [79] Woodall, J., Jr.; Tucci, M.; Mishra, A.; Benghuzzi, H. Cellular effects of platelet rich plasma: a study on HL-60 macrophage-like cells. *Biomed. Sci. Instrum.*, **2007**, *43*, 266-271.
- [80] Okuda, K.; Kawase, T.; Momose, M.; Murata, M.; Saito, Y.; Suzuki, H.; Wolff, L.F.; Yoshie, H. Platelet-rich plasma contains high levels of platelet-derived growth factor and transforming growth factor-beta and modulates the proliferation of periodontally related cells *in vitro*. *J. Periodontol.*, **2003**, *74*(6), 849-857.
- [81] Kilian, O.; Flesch, I.; Wenisch, S.; Taborski, B.; Jork, A.; Schnetler, R.; Jonuleit, T. Effects of platelet growth factors on human mesenchymal stem cells and human endothelial cells *in vitro*. *Eur. J. Med. Res.*, **2004**, *9*(7), 337-344.
- [82] Lucarelli, E.; Beccheroni, A.; Donati, D.; Sangiorgi, L.; Cenacchi, A.; Del Vento, A.M.; Meotti, C.; Bertoja, A.Z.; Giardino, R.; Fornasari, P.M.; Mercuri, M.; Picci, P. Platelet-derived growth factors enhance proliferation of human stromal stem cells. *Biomaterials*, **2003**, *24*(18), 3095-3100.
- [83] Vogel, J.P.; Szalay, K.; Geiger, F.; Kramer, M.; Richter, W.; Kasten, P. Platelet-rich plasma improves expansion of human mesenchymal stem cells and retains differentiation capacity and *in vivo* bone formation in calcium phosphate ceramics. *Platelets*, **2006**, *17*(7), 462-469.
- [84] Choi, B.H.; Zhu, S.J.; Kim, B.Y.; Huh, J.Y.; Lee, S.H.; Jung, J.H. Effect of platelet-rich plasma (PRP) concentration on the viability and proliferation of alveolar bone cells: an *in vitro* study. *Int. J. Oral Maxillofac. Surg.*, **2005**, *34*(4), 420-424.
- [85] Creeper, F.; Lichanska, A.M.; Marshall, R.I.; Seymour, G.J.; Ivanovski, S. The effect of platelet-rich plasma on osteoblast and periodontal ligament cell migration, proliferation and differentiation. *J. Periodontol. Res.*, **2009**, *44*(2), 258-265.
- [86] Graziani, F.; Ivanovski, S.; Cei, S.; Ducci, F.; Tonetti, M.; Gabriele, M. The *in vitro* effect of different PRP concentrations on osteoblasts and fibroblasts. *Clin. Oral Implants Res.*, **2006**, *17*(2), 212-219.
- [87] Gruber, R.; Varga, F.; Fischer, M.B.; Watzek, G. Platelets stimulate proliferation of bone cells: involvement of platelet-derived growth factor, microparticles and membranes. *Clin. Oral Implants Res.*, **2002**, *13*(5), 529-535.
- [88] Kawase, T.; Okuda, K.; Saito, Y.; Amizuka, N.; Suzuki, H.; Yoshie, H. Platelet-rich plasma provides nucleus for mineralization in cultures of partially differentiated periodontal ligament cells. *In Vitro Cell. Dev. Biol. Anim.*, **2005**, *41*(5-6), 171-176.
- [89] Kawase, T.; Okuda, K.; Saito, Y.; Yoshie, H. *In vitro* evidence that the biological effects of platelet-rich plasma on periodontal ligament cells is not mediated solely by constituent transforming-growth factor-beta or platelet-derived growth factor. *J. Periodontol.*, **2005**, *76*(5), 760-767.
- [90] Kawase, T.; Okuda, K.; Wolff, L.F.; Yoshie, H. Platelet-rich plasma-derived fibrin clot formation stimulates collagen synthesis in periodontal ligament and osteoblastic cells *in vitro*. *J. Periodontol.*, **2003**, *74*(6), 858-864.
- [91] Dohan Ehrenfest, D.M.; Diss, A.; Odin, G.; Doglioli, P.; Hippolyte, M.P.; Charrier, J.B. *In vitro* effects of Choukroun's PRF (platelet-rich fibrin) on human gingival fibroblasts, dermal prekeratinocytes, preadipocytes, and maxillofacial osteoblasts in primary cultures. *Oral Surg. Oral Med. Oral Pathol. Oral Radiol. Endod.*, **2009**, *108*(3), 341-352.
- [92] Dohan Ehrenfest, D.M.; Doglioli, P.; de Peppo, G.M.; Del Corso, M.; Charrier, J.B. Choukroun's platelet-rich fibrin (PRF) stimulates *in vitro* proliferation and differentiation of human oral bone mesenchymal stem cell in a dose-dependent way. *Arch. Oral Biol.*, **2010**, *55*(3), 185-194.
- [93] Dohan, D.M.; Del Corso, M.; Charrier, J.-B. Cytotoxicity analyses of Choukroun's PRF (Platelet Rich Fibrin) on a wide range of human cells: the answer to a commercial controversy. *Oral Surg. Oral Med. Oral Pathol. Oral Radiol. Endod.*, **2007**, *103*(5), 587-593.
- [94] Dohan Ehrenfest, D.M.; Vazquez, L. Pulling out, extraction or avulsion? *Implant Dent.*, **2008**, *17*(1), 4.
- [95] Rutkowski, J.L.; Fennell, J.W.; Kern, J.C.; Madison, D.E.; Johnson, D.A. Inhibition of alveolar osteitis in mandibular tooth extraction sites using platelet-rich plasma. *J. Oral Implantol.*, **2007**, *33*(3), 116-121.
- [96] Rutkowski, J.L.; Johnson, D.A.; Radio, N.M.; Fennell, J.W. Platelet rich plasma to facilitate wound healing following tooth extraction. *J. Oral Implantol.*, **2010**, *36*(1), 11-23.
- [97] Simon, D.; Manuel, S.; Geetha, V.; Naik, B.R. Potential for osseous regeneration of platelet-rich plasma--a comparative study in mandibular third molar sockets. *Indian J. Dent. Res.*, **2004**, *15*(4), 133-136.

- [98] Della Valle, A.; Sammartino, G.; Marenzi, G.; Tia, M.; Espedito di Lauro, A.; Ferrari, F.; Lo Muzio, L. Prevention of postoperative bleeding in anticoagulated patients undergoing oral surgery: use of platelet-rich plasma gel. *J. Oral Maxillofac. Surg.*, **2003**, *61*(11), 1275-1278.
- [99] Pessoa, R.S.; Oliveira, S.R.; Menezes, H.H.; de Magalhaes, D. Effects of platelet-rich plasma on healing of alveolar socket: split-mouth histological and histometric evaluation in Cebus apella monkeys. *Indian J. Dent. Res.*, **2009**, *20*(4), 442-447.
- [100] Sammartino, G.; Tia, M.; Marenzi, G.; di Lauro, A.E.; D'Agostino, E.; Claudio, P.P. Use of autologous platelet-rich plasma (PRP) in periodontal defect treatment after extraction of impacted mandibular third molars. *J. Oral Maxillofac. Surg.*, **2005**, *63*(6), 766-770.
- [101] Sammartino, G.; Tia, M.; Gentile, E.; Marenzi, G.; Claudio, P.P. Platelet-rich plasma and resorbable membrane for prevention of periodontal defects after deeply impacted lower third molar extraction. *J. Oral Maxillofac. Surg.*, **2009**, *67*(11), 2369-2373.
- [102] Gurbuzer, B.; Pikkoken, L.; Urhan, M.; Suer, B.T.; Narin, Y. Scintigraphic evaluation of early osteoblastic activity in extraction sockets treated with platelet-rich plasma. *J. Oral Maxillofac. Surg.*, **2008**, *66*(12), 2454-2460.
- [103] Arenaz-Bua, J.; Luaces-Rey, R.; Sironvalle-Soliva, S.; Otero-Rico, A.; Charro-Huerta, E.; Patino-Seijas, B.; Garcia-Rozado, A.; Ferreras-Granados, J.; Vazquez-Mahia, I.; Lorenzo-Franco, F.; Martin-Sastre, R.; Lopez-Cedrun, J.L. A comparative study of platelet-rich plasma, hydroxyapatite, demineralized bone matrix and autologous bone to promote bone regeneration after mandibular impacted third molar extraction. *Med. Oral Patol. Oral Cir. Bucal*, **2010**, *15*(3), e483-489.
- [104] Belli, E.; Longo, B.; Balestra, F.M. Autogenous platelet-rich plasma in combination with bovine-derived hydroxyapatite xenograft for treatment of a cystic lesion of the jaw. *J. Craniofac. Surg.*, **2005**, *16*(6), 978-980.
- [105] Shi, B.; Zhou, Y.; Wang, Y.N.; Cheng, X.R. Alveolar ridge preservation prior to implant placement with surgical-grade calcium sulfate and platelet-rich plasma: a pilot study in a canine model. *Int. J. Oral Maxillofac. Implants*, **2007**, *22*(4), 656-665.
- [106] Magremanne, M.; Baeyens, W.; Awada, S.; Vervae, C. Solitary bone cyst of the mandible and platelet rich fibrin (PRF). *Rev. Stomatol. Chir. Maxillofac.*, **2009**, *110*(2), 105-108.
- [107] Kotsovilis, S.; Markou, N.; Pepelassi, E.; Nikolidakis, D. The adjunctive use of platelet-rich plasma in the therapy of periodontal intraosseous defects: a systematic review. *J. Periodontol. Res.*, **2010**, *45*(3), 428-443.
- [108] Yilmaz, S.; Cakar, G.; Kuru, B.; Dirikan, S.; Yildirim, B. Platelet-rich plasma in combination with bovine derived xenograft in the treatment of deep intrabony periodontal defects: a report of 20 consecutively treated patients. *Platelets*, **2009**, *20*(6), 432-440.
- [109] Yilmaz, S.; Cakar, G.; Kuru, B.E.; Yildirim, B. Platelet-rich plasma in combination with bovine derived xenograft in the treatment of generalized aggressive periodontitis: a case report with re-entry. *Platelets*, **2007**, *18*(7), 535-539.
- [110] Demir, B.; Sengun, D.; Berberoglu, A. Clinical evaluation of platelet-rich plasma and bioactive glass in the treatment of intra-bony defects. *J. Clin. Periodontol.*, **2007**, *34*(8), 709-715.
- [111] Dori, F.; Kovacs, V.; Arweiler, N.B.; Huszar, T.; Gera, I.; Nikolidakis, D.; Sculean, A. Effect of platelet-rich plasma on the healing of intrabony defects treated with an anorganic bovine bone mineral: a pilot study. *J. Periodontol.*, **2009**, *80*(10), 1599-1605.
- [112] Dori, F.; Nikolidakis, D.; Huszar, T.; Arweiler, N.B.; Gera, I.; Sculean, A. Effect of platelet-rich plasma on the healing of intrabony defects treated with an enamel matrix protein derivative and a natural bone mineral. *J. Clin. Periodontol.*, **2008**, *35*(1), 44-50.
- [113] Harnack, L.; Boedeker, R.H.; Kurtulus, I.; Boehm, S.; Gonzales, J.; Meyle, J. Use of platelet-rich plasma in periodontal surgery—a prospective randomised double blind clinical trial. *Clin. Oral Investig.*, **2009**, *13*(2), 179-187.
- [114] Yassibag-Berkman, Z.; Tuncer, O.; Subasioglu, T.; Kantarci, A. Combined use of platelet-rich plasma and bone grafting with or without guided tissue regeneration in the treatment of anterior interproximal defects. *J. Periodontol.*, **2007**, *78*(5), 801-809.
- [115] Hanna, R.; Trejo, P.M.; Weltman, R.L. Treatment of intrabony defects with bovine-derived xenograft alone and in combination with platelet-rich plasma: a randomized clinical trial. *J. Periodontol.*, **2004**, *75*(12), 1668-1677.
- [116] Czuryzskiewicz-Cyryna, J.; Banach, J. Autogenous bone and platelet-rich plasma (PRP) in the treatment of intrabony defects. *Adv. Med. Sci.*, **2006**, *51* (Suppl 1), 26-30.
- [117] Okuda, K.; Tai, H.; Tanabe, K.; Suzuki, H.; Sato, T.; Kawase, T.; Saito, Y.; Wolff, L.F.; Yoshiex, H. Platelet-rich plasma combined with a porous hydroxyapatite graft for the treatment of intrabony periodontal defects in humans: a comparative controlled clinical study. *J. Periodontol.*, **2005**, *76*(6), 890-898.
- [118] Piemontese, M.; Aspriello, S.D.; Rubini, C.; Ferrante, L.; Procaccini, M. Treatment of periodontal intrabony defects with demineralized freeze-dried bone allograft in combination with platelet-rich plasma: a comparative clinical trial. *J. Periodontol.*, **2008**, *79*(5), 802-810.
- [119] Keles, G.C.; Cetinkaya, B.O.; Baris, S.; Albayrak, D.; Simsek, S.B. Comparison of platelet pellet with or without guided tissue regeneration in the treatment of class II furcation defects in dogs. *Clin. Oral Investig.*, **2009**, *13*(4), 393-400.
- [120] Papli, R.; Chen, S. Surgical treatment of intrabony defects with autologous platelet concentrate or bioabsorbable barrier membrane: a prospective case series. *J. Periodontol.*, **2007**, *78*(1), 185-193.
- [121] Markou, N.; Pepelassi, E.; Vavouraki, H.; Stamatakis, H.C.; Nikolopoulos, G.; Vrotsos, I.; Tsiklakis, K. Treatment of periodontal endosseous defects with platelet-rich plasma alone or in combination with demineralized freeze-dried bone allograft: a comparative clinical trial. *J. Periodontol.*, **2009**, *80*(12), 1911-1919.
- [122] Pradeep, A.R.; Pai, S.; Garg, G.; Devi, P.; Shetty, S.K. A randomized clinical trial of autologous platelet-rich plasma in the treatment of mandibular degree II furcation defects. *J. Clin. Periodontol.*, **2009**, *36*(7), 581-588.
- [123] Pradeep, A.R.; Shetty, S.K.; Garg, G.; Pai, S. Clinical effectiveness of autologous platelet-rich plasma and Peptide-enhanced bone graft in the treatment of intrabony defects. *J. Periodontol.*, **2009**, *80*(1), 62-71.
- [124] Keles, G.C.; Cetinkaya, B.O.; Albayrak, D.; Koprulu, H.; Acikgoz, G. Comparison of platelet pellet and bioactive glass in periodontal regenerative therapy. *Acta Odontol. Scand.*, **2006**, *64*(6), 327-333.
- [125] Camargo, P.M.; Lekovic, V.; Weinlaender, M.; Vasilic, N.; Madzarevic, M.; Kenney, E.B. A reentry study on the use of bovine porous bone mineral, GTR, and platelet-rich plasma in the regenerative treatment of intrabony defects in humans. *Int. J. Periodontics Restorative Dent.*, **2005**, *25*(1), 49-59.
- [126] Lekovic, V.; Camargo, P.M.; Weinlaender, M.; Vasilic, N.; Aleksic, Z.; Kenney, E.B. Effectiveness of a combination of platelet-rich plasma, bovine porous bone mineral and guided tissue regeneration in the treatment of mandibular grade II molar furcations in humans. *J. Clin. Periodontol.*, **2003**, *30*(8), 746-751.
- [127] Camargo, P.M.; Lekovic, V.; Weinlaender, M.; Vasilic, N.; Madzarevic, M.; Kenney, E.B. Platelet-rich plasma and bovine porous bone mineral combined with guided tissue regeneration in the treatment of intrabony defects in humans. *J. Periodontol. Res.*, **2002**, *37*(4), 300-306.
- [128] Camargo, P.M.; Lekovic, V.; Weinlaender, M.; Divnic-Resnik, T.; Pavlovic, M.; Kenney, E.B. A surgical reentry study on the influence of platelet-rich plasma in enhancing the regenerative effects of bovine porous bone mineral and guided tissue regeneration in the treatment of intrabony defects in humans. *J. Periodontol.*, **2009**, *80*(6), 915-923.
- [129] Dori, F.; Huszar, T.; Nikolidakis, D.; Arweiler, N.B.; Gera, I.; Sculean, A. Effect of platelet-rich plasma on the healing of intrabony defects treated with an anorganic bovine bone mineral and expanded polytetrafluoroethylene membranes. *J. Periodontol.*, **2007**, *78*(6), 983-990.
- [130] Dori, F.; Huszar, T.; Nikolidakis, D.; Arweiler, N.B.; Gera, I.; Sculean, A. Effect of platelet-rich plasma on the healing of intrabony defects treated with a natural bone mineral and a collagen membrane. *J. Clin. Periodontol.*, **2007**, *34*(3), 254-261.
- [131] Dori, F.; Huszar, T.; Nikolidakis, D.; Tihanyi, D.; Horvath, A.; Arweiler, N.B.; Gera, I.; Sculean, A. Effect of platelet-rich plasma on the healing of intrabony defects treated with Beta tricalcium phosphate and expanded polytetrafluoroethylene membranes. *J. Periodontol.*, **2008**, *79*(4), 660-669.
- [132] Lekovic, V.; Camargo, P.M.; Weinlaender, M.; Vasilic, N.; Kenney, E.B. Comparison of platelet-rich plasma, bovine porous bone mineral, and guided tissue regeneration versus platelet-rich plasma and bovine porous bone mineral in the treatment of intrabony defects: a reentry study. *J. Periodontol.*, **2002**, *73*(2), 198-205.

- [133] Chang, T.; Liu, Q.; Marino, V.; Bartold, P.M. Attachment of periodontal fibroblasts to barrier membranes coated with platelet-rich plasma. *Aust. Dent. J.*, **2007**, 52(3), 227-233.
- [134] Okuda, K.; Yamamiya, K.; Kawase, T.; Mizuno, H.; Ueda, M.; Yoshie, H. Treatment of human infrabony periodontal defects by grafting human cultured periosteum sheets combined with platelet-rich plasma and porous hydroxyapatite granules: case series. *J. Int. Acad. Periodontol.*, **2009**, 11(3), 206-213.
- [135] Yamamiya, K.; Okuda, K.; Kawase, T.; Hata, K.; Wolff, L.F.; Yoshie, H. Tissue-engineered cultured periosteum used with platelet-rich plasma and hydroxyapatite in treating human osseous defects. *J. Periodontol.*, **2008**, 79(5), 811-818.
- [136] Tobita, M.; Uysal, A.C.; Ogawa, R.; Hyakusoku, H.; Mizuno, H. Periodontal tissue regeneration with adipose-derived stem cells. *Tissue Eng. Part A*, **2008**, 14(6), 945-953.
- [137] Demiralp, B.; Keceli, H.G.; Muhtarogullar, M.; Serper, A.; Eratalay, K. Treatment of periapical inflammatory lesion with the combination of platelet-rich plasma and tricalcium phosphate: a case report. *J. Endod.*, **2004**, 30(11), 796-800.
- [138] Hiremath, H.; Gada, N.; Kini, Y.; Kulkarni, S.; Yakub, S.S.; Metgud, S. Single-step apical barrier placement in immature teeth using mineral trioxide aggregate and management of periapical inflammatory lesion using platelet-rich plasma and hydroxyapatite. *J. Endod.*, **2008**, 34(8), 1020-1024.
- [139] Tozum, T.F.; Keceli, H.G.; Serper, A.; Tuncel, B. Intentional replantation for a periodontally involved hopeless incisor by using autologous platelet-rich plasma. *Oral Surg. Oral Med. Oral Pathol. Oral Radiol. Endod.*, **2006**, 101(6), e119-124.
- [140] Demir, B.; Demiralp, B.; Guncu, G.N.; Uyanik, M.O.; Caglayan, F. Intentional replantation of a hopeless tooth with the combination of platelet rich plasma, bioactive glass graft material and non-resorbable membrane: a case report. *Dent. Traumatol.*, **2007**, 23(3), 190-194.
- [141] Dohan Ehrenfest, D.M.; de Peppo, G.M.; Doglioli, P.; Sammartino, G. Slow release of growth factors and thrombospondin-1 in Choukroun's platelet-rich fibrin (PRF): a gold standard to achieve for all surgical platelet concentrates technologies. *Growth Factors*, **2009**, 27(1), 63-69.
- [142] Dohan Ehrenfest, D.M. How to optimize the preparation of leukocyte- and platelet-rich fibrin (L-PRF, Choukroun's technique) clots and membranes: introducing the PRF Box. *Oral Surg. Oral Med. Oral Pathol. Oral Radiol. Endod.*, **2010**, 110(3), 275-278.
- [143] Choukroun, J.; Adda, F.; Schoeffler, C.; Vervelle, A. Une opportunité en parodontologie : le PRF. *Implantodontie*, **2001**, 42, 55-62.
- [144] Choukroun, J.; Simonpieri, A.; Del Corso, M.; Mazor, Z.; Sammartino, G.; Dohan Ehrenfest, D.M. Controlling systematic perioperative anaerobic contamination during sinus-lift procedures by using metronidazole: an innovative approach. *Implant Dent.*, **2008**, 17(3), 257-270.
- [145] Gassling, V.; Douglas, T.; Warnke, P.H.; Acil, Y.; Wiltfang, J.; Becker, S.T. Platelet-rich fibrin membranes as scaffolds for periosteal tissue engineering. *Clin. Oral Implants Res.*, **2010**, 21(5), 543-549.
- [146] Lindeboom, J.A.; Mathura, K.R.; Aartman, I.H.; Kroon, F.H.; Milstein, D.M.; Ince, C. Influence of the application of platelet-enriched plasma in oral mucosal wound healing. *Clin. Oral Implants Res.*, **2007**, 18(1), 133-139.
- [147] Powell, C.A.; Bannister, S.R.; Mackey, S.A.; Maller, S.C.; McDonnell, H.T.; Deas, D.E. Periodontal wound healing with and without platelet-rich plasma: histologic observations and assessment of flap tensile strength. *J. Periodontol.*, **2009**, 80(6), 985-992.
- [148] Saadoun, A.P. Current trends in gingival recession coverage--Part II: Enamel matrix derivative and platelet-rich plasma. *Pract. Proced. Aesthet. Dent.*, **2006**, 18(8), 521-526; quiz 528.
- [149] Steinberg, A.D.; LeBreton, G.; Willey, R.; Mukherjee, S.; Lipowski, J. Extravascular clot formation and platelet activation on variously treated root surfaces. *J. Periodontol.*, **1986**, 57(8), 516-522.
- [150] Trombelli, L.; Scabbia, A.; Wikesjo, U.M.; Calura, G. Fibrin glue application in conjunction with tetracycline root conditioning and coronally positioned flap procedure in the treatment of human gingival recession defects. *J. Clin. Periodontol.*, **1996**, 23(9), 861-867.
- [151] Bashutski, J.D.; Wang, H.L. Role of platelet-rich plasma in soft tissue root-coverage procedures: a review. *Quintessence Int.*, **2008**, 39(6), 473-483.
- [152] Keceli, H.G.; Sengun, D.; Berberoglu, A.; Karabulut, E. Use of platelet gel with connective tissue grafts for root coverage: a randomized-controlled trial. *J. Clin. Periodontol.*, **2008**, 35(3), 255-262.
- [153] Suaid, F.F.; Carvalho, M.D.; Santamaria, M.P.; Casati, M.Z.; Nociti, F.H., Jr.; Sallum, A.W.; Sallum, E.A. Platelet-rich plasma and connective tissue grafts in the treatment of gingival recessions: a histometric study in dogs. *J. Periodontol.*, **2008**, 79(5), 888-895.
- [154] Shepherd, N.; Greenwell, H.; Hill, M.; Vidal, R.; Scheetz, J.P. Root coverage using acellular dermal matrix and comparing a coronally positioned tunnel with and without platelet-rich plasma: a pilot study in humans. *J. Periodontol.*, **2009**, 80(3), 397-404.
- [155] Shayesteh, Y.S.; Eshghyar, N.; Moslemi, N.; Dehghan, M.M.; Motahary, P.; Ghobadi, Z.; Golestan, B. The effect of platelet-rich plasma on healing of palatal donor site following connective tissue harvesting: a pilot study in dogs. *Clin. Implant Dent. Relat. Res.*, 2010. [Epub ahead of print].
- [156] Su, C.Y.; Kuo, Y.P.; Tseng, Y.H.; Su, C.H.; Burnouf, T. *In vitro* release of growth factors from platelet-rich fibrin (PRF): a proposal to optimize the clinical applications of PRF. *Oral Surg. Oral Med. Oral Pathol. Oral Radiol. Endod.*, **2009**, 108(1), 56-61.
- [157] He, L.; Lin, Y.; Hu, X.; Zhang, Y.; Wu, H. A comparative study of platelet-rich fibrin (PRF) and platelet-rich plasma (PRP) on the effect of proliferation and differentiation of rat osteoblasts *in vitro*. *Oral Surg. Oral Med. Oral Pathol. Oral Radiol. Endod.*, **2009**, 108(5), 707-713.
- [158] Mizuno, D.; Kagami, H.; Mizuno, H.; Mase, J.; Usami, K.; Ueda, M. Bone regeneration of dental implant dehiscence defects using a cultured periosteum membrane. *Clin. Oral Implants Res.*, **2008**, 19(3), 289-294.
- [159] de Vasconcelos Gurgel, B.C.; Goncalves, P.F.; Pimentel, S.P.; Ambrosano, G.M.; Nociti Junior, F.H.; Sallum, E.A.; Casati, M.Z. Platelet-rich plasma may not provide any additional effect when associated with guided bone regeneration around dental implants in dogs. *Clin. Oral Implants Res.*, **2007**, 18(5), 649-654.
- [160] Kassolis, J.D.; Rosen, P.S.; Reynolds, M.A. Alveolar ridge and sinus augmentation utilizing platelet-rich plasma in combination with freeze-dried bone allograft: case series. *J. Periodontol.*, **2000**, 71(10), 1654-1661.
- [161] Shanaman, R.; Filstein, M.R.; Danesh-Meyer, M.J. Localized ridge augmentation using GBR and platelet-rich plasma: case reports. *Int. J. Periodontics Restorative Dent.*, **2001**, 21(4), 345-355.
- [162] Wojtowicz, A.; Chaberek, S.; Kryst, L.; Urbanowska, E.; Ciechowicz, K.; Ostrowski, K. Fourier and fractal analysis of maxillary alveolar ridge repair using platelet rich plasma (PRP) and inorganic bovine bone. *Int. J. Oral Maxillofac. Surg.*, **2003**, 32(1), 84-86.
- [163] Bannister, S.R.; Powell, C.A. Foreign body reaction to anorganic bovine bone and autogenous bone with platelet-rich plasma in guided bone regeneration. *J. Periodontol.*, **2008**, 79(6), 1116-1120.
- [164] Kfir, E.; Kfir, V.; Kaluski, E. Immediate bone augmentation after infected tooth extraction using titanium membranes. *J. Oral Implantol.*, **2007**, 33(3), 133-138.
- [165] Mouhyi, J.; Dohan Ehrenfest, D.M.; Albrektsson, T. The peri-implantitis: Implant surfaces, microstructure, and physicochemical aspects. *Clin. Implant Dent. Relat. Res.*, 2009 [Epub ahead of print].
- [166] Dohan Ehrenfest, D.M.; Coelho, P.G.; Kang, B.S.; Sul, Y.T.; Albrektsson, T. Classification of osseointegrated implant surfaces: materials, chemistry and topography. *Trends Biotechnol.*, **2010**, 28(4), 198-206.