

## Immediately loaded dental implants bioactivated with platelet-rich plasma (PRP) placed in maxillary and mandibular region

F. Inchingolo<sup>1</sup>, A. Ballini<sup>2</sup>, R. Cagiano<sup>3</sup>, A.D. Inchingolo<sup>1</sup>, M. Serafini<sup>1</sup>, M. De Benedittis<sup>1</sup>, R. Cortelazzi<sup>1</sup>, M. Tatullo<sup>4</sup>, M. Marrelli<sup>1</sup>, A.M. Inchingolo<sup>1</sup>, D. Vermesan<sup>5</sup>, M. Del Corso<sup>1</sup>, G. Malcangi<sup>1</sup>, S. Diteodoro<sup>4</sup>, S.A. Mura<sup>1</sup>, S. Cantore<sup>2</sup>, A. Cortelazzi<sup>1</sup>, G. Paduanelli<sup>1</sup>, G. Resta<sup>1</sup>, F. Muollo<sup>1</sup>, N. Cirulli<sup>2</sup>, F. Pettini<sup>1</sup>, D. Farronato<sup>6</sup>, D. De Vito<sup>2</sup>, M. Caprio<sup>3</sup>, H. Haragus<sup>5</sup>, G. Dipalma<sup>1</sup>

Departments of <sup>1</sup>Interdisciplinary Medicine; <sup>2</sup>Basic Medical Sciences, Neurosciences and Sense organs; <sup>3</sup>Biomedical Sciences and Human Oncology, University "Aldo Moro", Bari, Italy; <sup>4</sup>Calabrodental Clinic, Regenerative Medicine Section, Tecnologica Research Institute, Crotona, Italy; <sup>5</sup>University of Medicine and Pharmacy "Victor Babes" Timisoara, Romania; <sup>6</sup>Department of Morphologic and Surgical Sciences, Insubria University, Varese, Italy

### Abstract

**Background and Aim.** Dental implants have today deeply changed the dental field. In fact, after almost 50 years, the permanent placement of a titanium screw with an attached tooth have, step by step, changed the society's standard toward a permanently replacement of missed or severely damaged teeth. In fact, the host of benefits born from dental implants have affected both patients and dental professionals. The aim of the present study is to report the outcomes of an implant therapy protocol supporting fixed prostheses implanted soon after extractions and loaded with flapless guided surgery by a 3D software planning.

**Materials and Methods.** 37 patients, requiring rehabilitation of booth dental arches with a one-to-one technique, were enrolled in a follow-up study plan which established clinical and radiological examinations on the day after surgery, seven months and one year later. Platelet Rich Plasma (PRP), in combination with autogenous bone, organic bone material and organic bone substitutes, was used before implant-prosthetic rehabilitation with an its prompt loading just before the implant insertion phase.

**Results.** Definitive restorations were delivered at 6-12 months after surgical procedure. One year after loading there were no dropouts and no failure of the definitive prosthesis. Furthermore, the feedback from patients resulted positive.

**Conclusion.** Patients resulted satisfied both aesthetically and functionally regarding these types of prosthetic reconstructions made at the time. *Clin Ter 2015; 166(3):e146-152. doi: 10.7417/CT.2015.1845*

**Key words:** computerized implant software, dental implants, immediate loading, oral rehabilitation, platelet-rich plasma

### Introduction

For experienced specialists in oral surgery and prosthetics, to restore one or two individual dental elements is relatively simple clinically and technically but, when the

need arises to restore multiple elements in areas with major aesthetic interest, prosthetic restoration is a challenge for any professional team. In many cases, dental implants may be the only consistent and successive choice for the restoration of all necessary functionality of the teeth and supporting structures. (1-3). It is possible to successfully load dental implants immediately or early after their placement in selected patients, although not all clinicians may achieve optimal results (1). A high degree of primary implant stability (high value of insertion torque) seems to be one of the prerequisites for a successful immediate/early loading procedure (1). Despite the high success rate of dental implants, the osteo-regenerative potential of the surrounding tissues (soft and hard) that substantially affect the outcome of the overall surgical procedure, still remains an important issue (2). In order to promote the healing of the end-osseous implants and bone grafts, various procedures have been proposed (4). The majority of these proposals concentrate on strengthening the bone-to-implant contact area in order to accelerate the osseous healing. These include the application of Platelet Rich Plasma (PRP) together with bone morphogenetic proteins (BMPs) and growth factors. PRP is a new approach to tissue regeneration and it is becoming a valuable adjunct to promote healing in dental and oral surgery procedures, especially in aging patients (5). PRP derives from the centrifugation of the patient's own blood and contains growth factors which influence wound healing and, thereby, playing an important role in tissue repairing mechanisms (6). The use of PRP in surgical practice could have beneficial outcomes, reducing bleeding and enhancing soft tissue healing and bone regeneration (5-8).

The purpose of the present study was to demonstrate the efficacy of a procedure concerning the use of PRP as platelet concentrate, in combination with autogenous bone, organic bone material and organic bone substitutes in an immediate loading one-to-one implant-prosthetic rehabilitation.

## Materials and Methods

### Patients

Thirty-seven patients (23 males and 14 females) aged 45-65 years (mean age 55 years) were selected from multi-centric private practice dental cabinets in Chieti, Turin, Bari, Crotone and Milan. Only those patients who resulted to have missing/compromised multiple teeth, both in maxillary and mandibular region with healed edentulous area for at least six months, were considered. An informed consent was obtained from all patients before starting the treatment.

### Inclusion criteria

- 1) patients having multiple consecutively edentulous space both in maxillary and mandibular region and with compromised dental elements needing multiple extractions;
- 2) adequate bone quantity and quality at the implant site;
- 3) patients well motivated for implant therapy and maintaining good oral hygiene.

### Exclusion criteria

- 1) medically compromised or patients taking any immunosuppressive drugs which may complicate the treatment outcome,

- 2) infection around the implant site, 3) history of bruxism/parafunctional habits, 4) patients with history of any bleeding disorder or subjected to anti-coagulant therapy.

### Preparation of PRP

As reported in our previous scientific papers (5), the patients were subjected to complete haemogram analysis. Before starting the surgical procedure, 5 ml of venous blood, drawn from the antecubital vein of each patient, was picked up in sterile Vacutainer containing 1 ml Citrate Phosphate Dextrose-Adenine (CPDA) as anticoagulant and centrifuged at 2400 rpm for 10 minutes. After the first centrifugation, two layers were clearly seen into the Vacutainer. An upper yellow layer consisting of platelet rich and poor plasma and a lower red layer consisting of erythrocytes and leukocytes. Then the complete upper yellow layer and top part (1-2 mm) of the lower red layer were transferred into a plain Vacutainer. After a second centrifugation at 3600 rpm for 15 minutes, two layers were visible into the Vacutainer: approximately 1ml of plasma rich of platelets at bottom and the upper part with plasma poor of platelets. The part of platelet poor plasma was discarded while the remaining plasma at bottom stored in a platelet agitator until its use.

### Surgical procedure

Radiographic and clinical examinations were conducted prior the surgical procedure (Fig. 1 A-B). The treatment plan

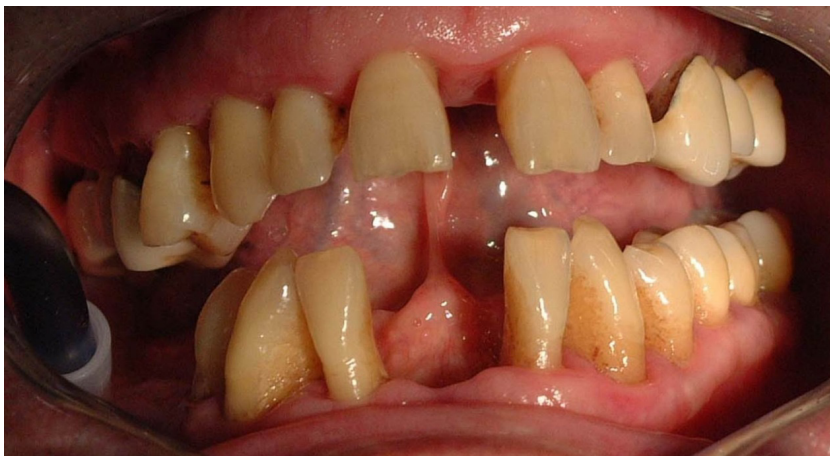

Fig. 1.A. Clinical examination prior the surgical procedure..

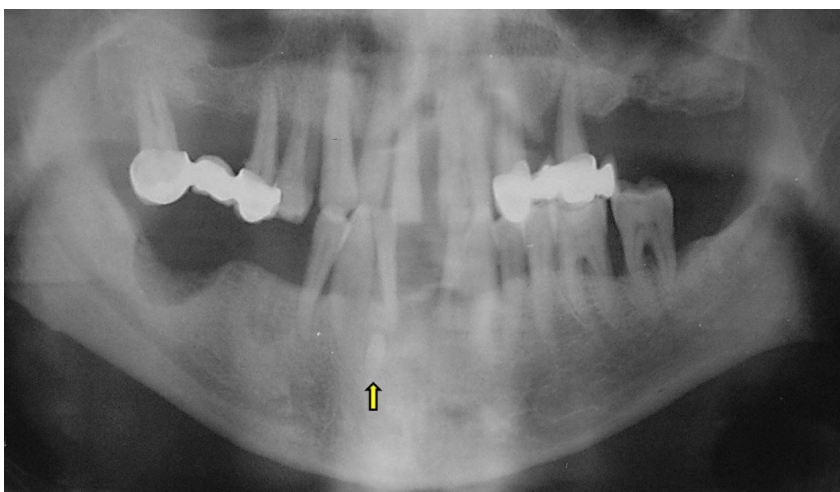


Fig. 1.B. Orthopantomographic examination prior the surgical procedure.

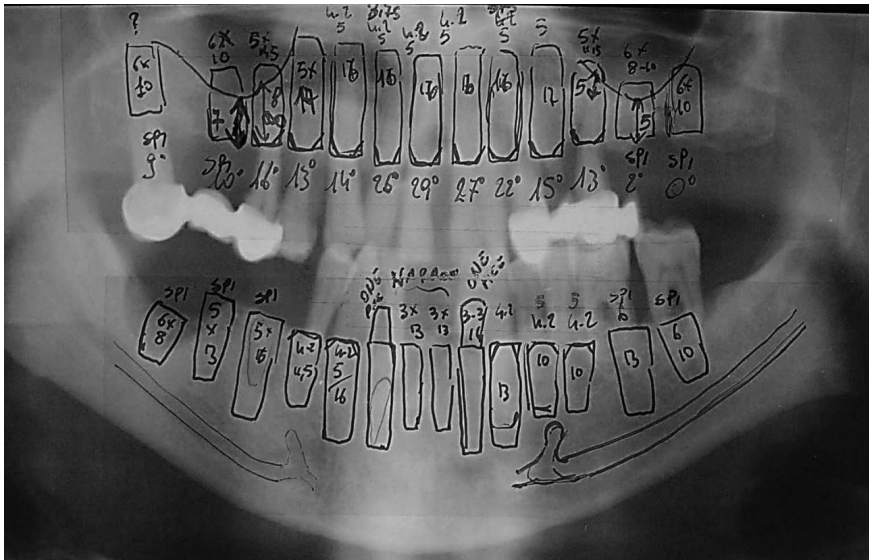


Fig. 2. Preliminary locations and types of implants were selected from Orthopantomogram

consisted in teeth extractions with subsequent immediate loading of maxillary and mandibular implant supported by fixed complete dentures (in post-extraction sites). Following an esthetical and functional analysis, the dentures were duplicated and served as radiographic templates worn during the CT scan. After the available bone and other prosthodontic treatment, criteria were evaluated (9-11) and the locations

and types of implants were selected (Fig. 2). The implants were mounted virtually with a dental software (Implant3D®) on the selected sections and angulations, where depths and diameters were assessed (Fig. 3 A-B). Parallelism of the implants was also controlled and corrected. Once implant selection and positioning have been determined, the system converts the radiographic template to a surgical guide with

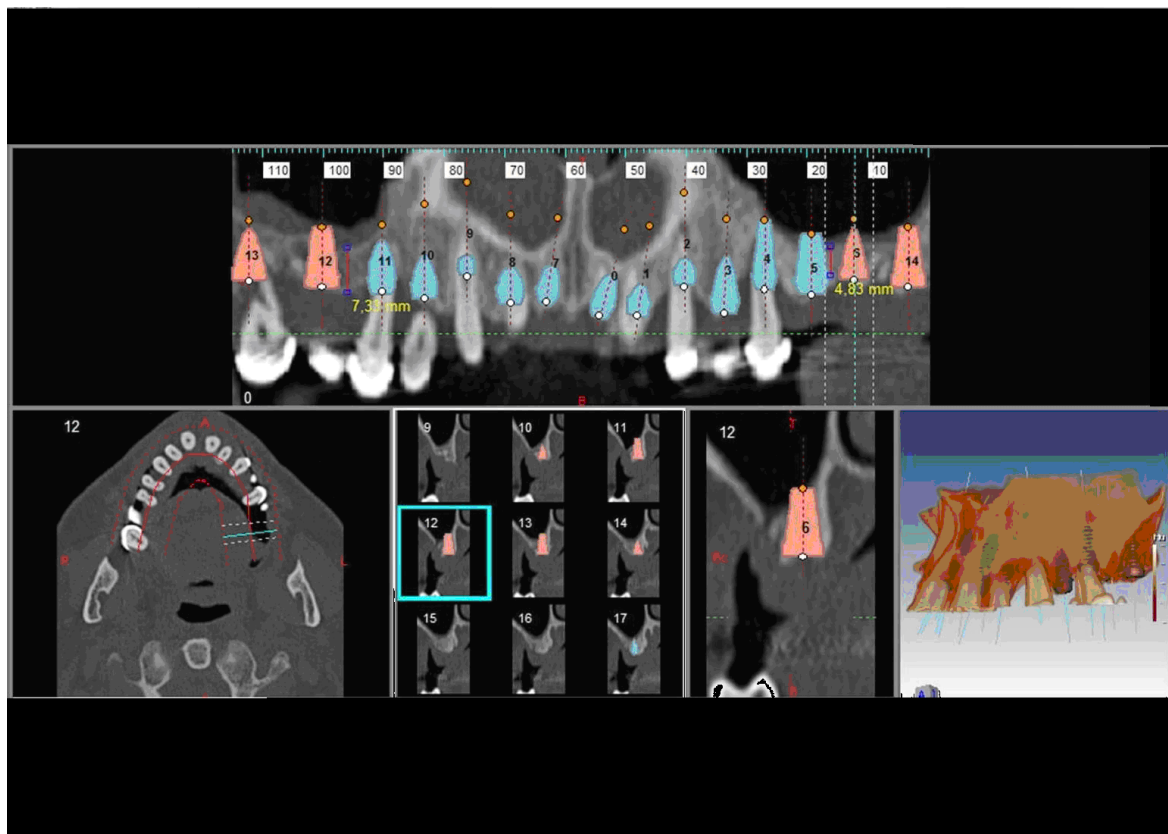


Fig. 3.A. Computed guided selection, positioning and parallelism of the implants in the receiving maxillary sites.



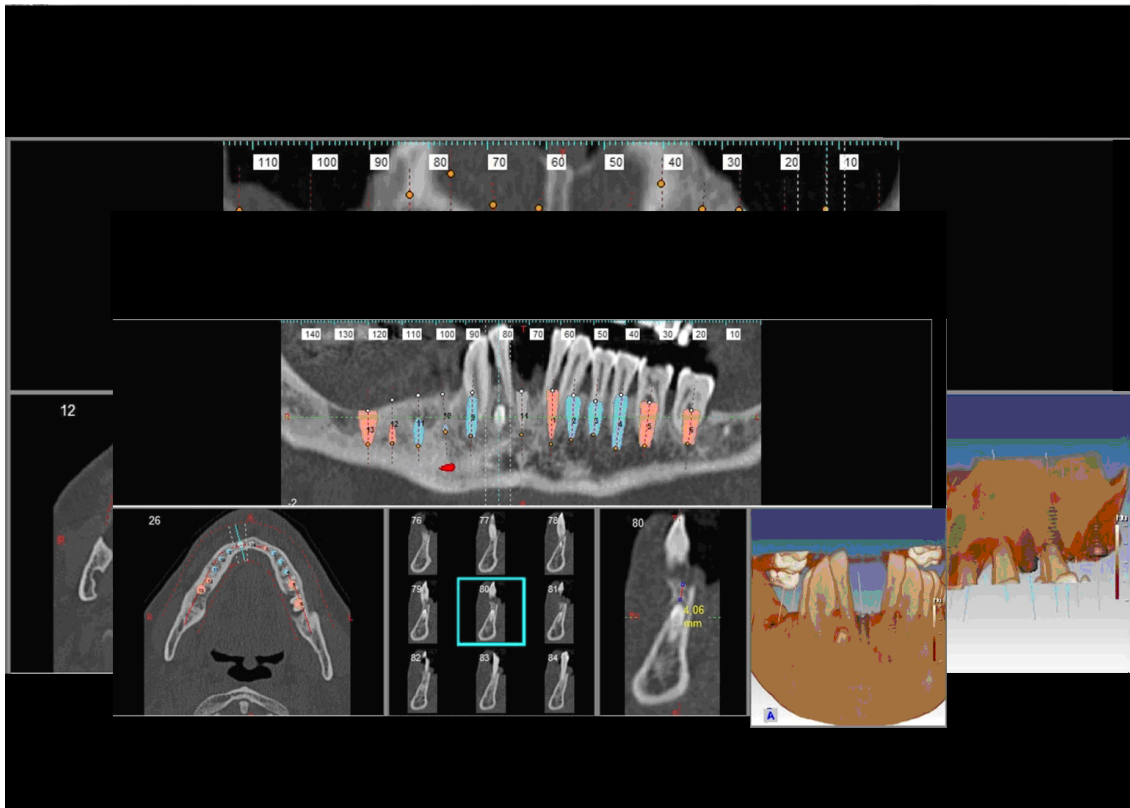


Fig. 3.B: Computed guided selection, positioning and parallelism of the implants in the receiving mandibular sites.

incorporated drill housing (Fig. 3 A-B). One-to-one implants (Spiral Implant with Sand blast Large grit Acid etch (SLA), MIS® Implants Technologies Ltd-Israel) were placed with a flapless guided surgical approach and, in post-extraction sites, were immediately loaded provisional restoration.

The criteria for flapless surgery were:

1. Adequate amount of bone for implant placement with a presence of 1 mm of buccolingual bone to the planned implant in a favorable prosthetic position, as determined by CT analysis, and
2. sufficient attached mucosa present at the surgical site such that at least 2 mm of the attached gingiva remaining circumferentially around the implant site.

After anesthesia, the surgical guide was secured over the untouched site by transfixing the guide flanges through gingival tissues up to the bone using a bone drill as guide stabilizers. Following the preparation of the receiving site, it was thoroughly irrigated with saline solution in order to clear any bone debris accidentally present at the site. Just prior its placement, the implant was dipped in activated PRP solution contained in an autoclaved dappen-dish, taking care in avoiding any contact with the walls of the container in order to prevent any possible contamination of the implant surface, which could be detrimental for a successful osteointegration. PRP was used in combination with autogenous bone, an organic bone material and organic (equine/porcine) bone substitutes (Fig. 4), and the implants placed in the receiving sites (Fig. 5 A-B). Mandibular rehabilitation was performed one month after maxillary surgery, in order to prevent patients discomfort (Fig. 5 C). To perform immediate loading,

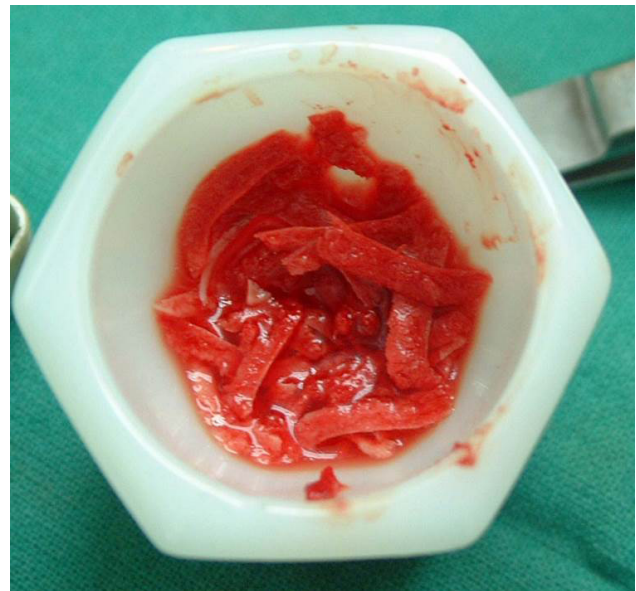


Fig. 4. PRP in combination with autogenous bone.

the implants had to be inserted with torque of at least 35 Ncm (12). Provisional prostheses were made before surgery using software planning and were placed in the same session as the implants. The provisional prosthesis was cemented with zinc oxide non-eugenol temporary cement within a period of two weeks, following the protocol of immediate loading. Radiographs were assessed before the implant placement, at

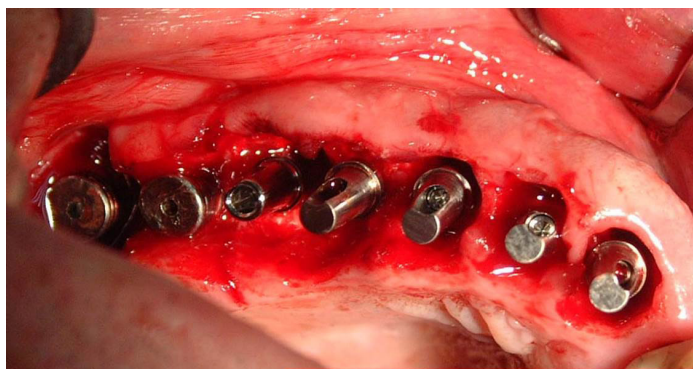


Fig. 5 A-B. Implants placed in the receiving maxillary sites.

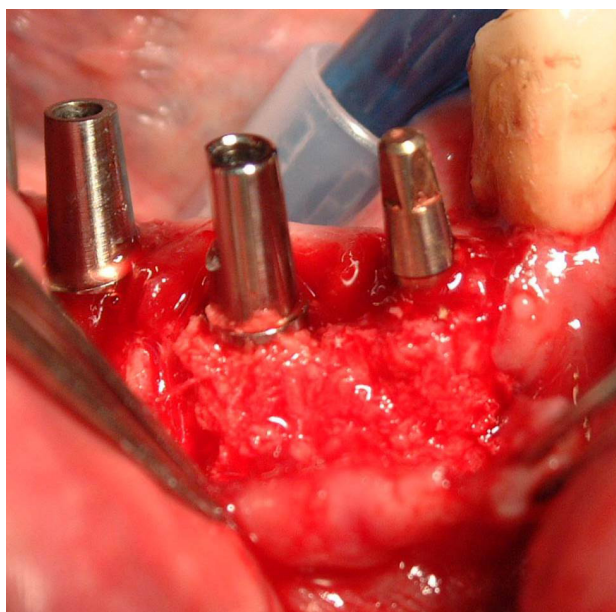
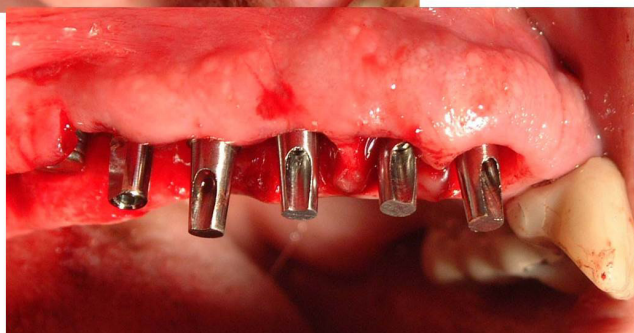

Fig. 5.C. Implants placed in the receiving and mandibular sites.

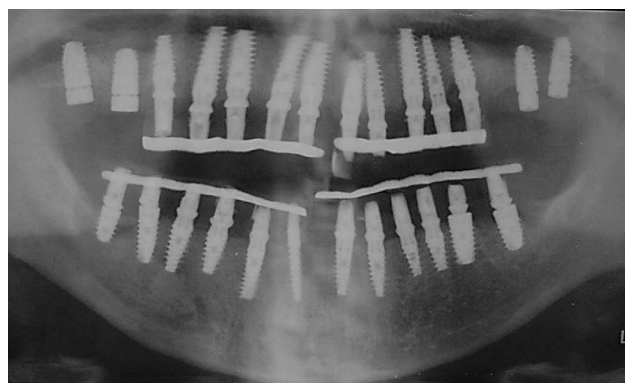


Fig. 6. Immediate post-operative radiograph.

#### *Fabrication of prosthesis*

Definitive restorations were delivered 6-12 months after surgery. Outcome measures were made regarding eventual failures of the prosthesis and of the implants, marginal bone level changes, complications, clinical time and patient satisfaction. Full-arch maxillary and mandibular polyether impressions were made after one month from surgery. The maxillary final restoration was made with zirconia10, taking in consideration, for the vertical dimension, the patient's high-lip-smile and, for the anterior-posterior horizontal dimension, if the patient had needing of an adequate lip-support (Fig. 7). The mandibular restoration denture was in zirconia elements (10). All final prostheses were fitted and the occlusion verified (Fig. 8).

#### *Clinical parameters*

After implant placement, clinical parameters were recorded and evaluated at baseline and at 3, 6, 9, and 12 months postoperatively. The clinical parameters recorded were: modified plaque index (11), modified gingival index

the time of implant placement (Fig. 6). Patients were given post-operative instructions and prescribed antibiotics (amoxicillin/clavulanic acid 1,000 mg 8 hourly, for five days), analgesics/anti-inflammatory drugs (ibuprofen 400 mg TDS, for three days), and mouthwash with clorexidine in depth around the implant at four sites using the "Tissue pressure sensitive" (TPS) probe (13), implant mobility (according to clinical implant mobility scale) (14) and the absence or presence of any infection around the implant.



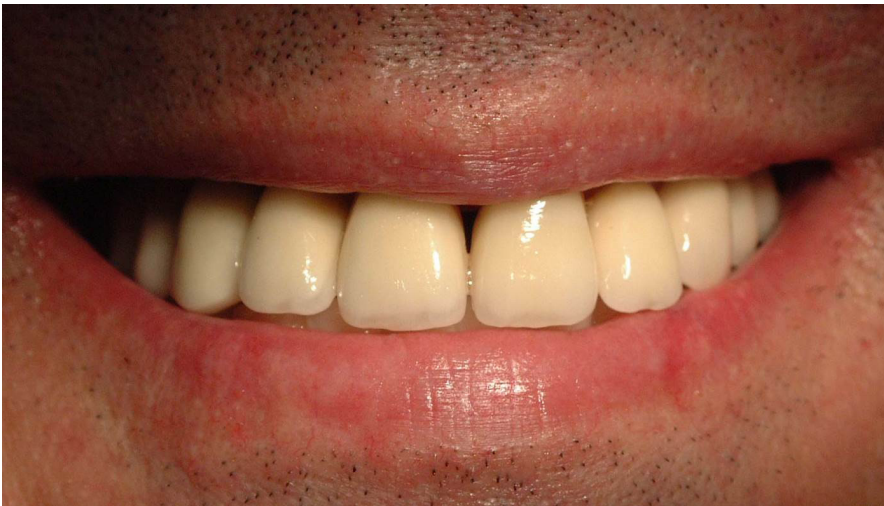

Fig. 7. The maxillary final restoration, made in zirconia, taking in consideration high-lip-smile and patient's need for an adequate lip-support.

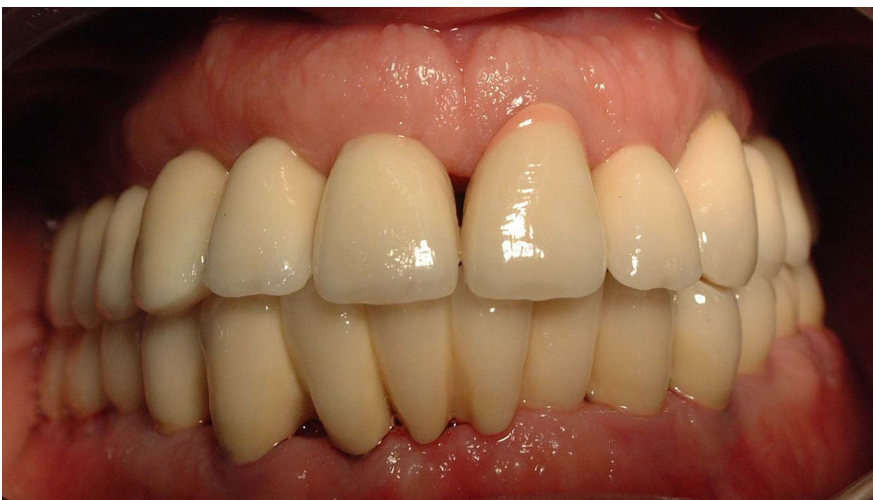

Fig. 8. Permanent prosthesis cemented and occlusion verified.

(12), probing depth around the implant at four sites using the TPS probe (13), implant mobility (according to clinical implant mobility scale) (14) and the absence or presence of any periodontal infection around the implant and the surrounding tissue (11,15).

## Results

The definitive prostheses provided in all patients excellent facial support, phonetics, esthetics, smile line and function. None of the immediate loaded implants showed any mobility during the observational period. At the one year follow up the patients were instructed how to brush their teeth in order to improve their oral hygiene also showing auxiliary cleaning methods. All patients showed excellent personal dental hygiene. Clinically, we noticed, as reported from scientific literature (6,8) that the growth factors in PRP increased epithelial wound healing, decrease tissue inflammation after surgery, improve the regeneration of bone and soft tissues, and promote tissue vascularization. The additional advantages related to the use of this product are its biocompatibility and safety, as an autologous product.

One year after loading there were no dropouts and no failure of the definitive prosthesis.

## Discussion

In the present study, all enrolled patients participated until the end of the study reporting no clinical dropout and showing good compliance in oral hygiene maintenance. They followed all specified instructions and no complication was recorded in some of the treated cases. Recording and radiographic evaluations, performed after 6 and 12 months from the immediate loading of the bioactivated implants, resulted successful. Healing, in general, was uneventful with minimal discomfort for all the patients; all the treated sites maintained excellent peri-implant soft and hard tissue conditions. PRP preparations have been proposed for several uses both in dental and oral surgery (5); the use of PRP may lead to improved early bone apposition around the implant and thus results in an increased rate of osteointegration (16). The easiness in using these preparations might be helpful to the dental professionals in many surgical procedures and their safety might encourage to their wider employment. The

commercial exploitation of these growth factors has led to the development of a wide range of preparation protocols, kits and centrifuges. The scientific evidence regarding the efficacy and efficiency of PRP is still controversial, given the paucity of RCTs related to this topic and, among these, the majority has been conducted using different graft materials and applying different procedures (9). A software-based treatment planning may be useful in planning and treating challenging cases such as flapless implant placement and immediate loading of maxillary cross-arch bridges (17, 18). Single stage implant procedure, with the adjunctive use of PRP, enhances the ability of the peri-implant healing tissue in creating favorable soft and hard tissue relationships (5, 17). It also gives the added advantage of psychological boost for the patient by getting fixed replacement of tooth within a short time period. However, according to evidence based dentistry, this technique could be sensitive to the experience of the surgeon and a learning curve is required (17, 19-20). The feedback from patients resulted positive. Although these therapeutic solutions show some disadvantages, such as an high cost, the needing for an accurate and valid preparation is extremely critical for benefits went to patients.

#### Conflict of interests

Authors declare no conflict of interest.

#### References

- Esposito M, Grusovin MG, Willings M, et al. The effectiveness of immediate, early, and conventional loading of dental implants: a Cochrane systematic review of randomized controlled clinical trials. *Int J Oral & Maxillofac Implants* 2007; 22(6):893-900
- Esposito M, Grusovin MG, Maghairyeh H, et al. Interventions for replacing missing teeth: different times for loading dental implants. *Cochrane Database Syst Rev* 2013; 3:CD003878
- Trisi P. Why Science? Why Research? *Implant Dentistry*. 2008; 17(4):373-4
- Youssif A, Chowdhury MU, Ray S. Computer Aided Analysis of Dental Radiographic Images. *Proceedings of the Digital Image Computing: Techniques and Applications*. 2005; 43-8
- Inchingolo F, Tatullo M, Marrelli M, et al. Regenerative surgery performed with platelet-rich plasma used in sinus lift elevation before dental implant surgery: an useful aid in healing and regeneration of bone tissue. *Eur Rev Med Pharmacol Sci* 2012; 16(9):1222-6
- Georgakopoulos I, Tsantis S, Georgakopoulos P, et al. The impact of Platelet Rich Plasma (PRP) in osseointegration of oral implants in dental panoramic radiography: texture based evaluation. *Clin Cases Miner Bone Metab* 2014; 11(1):59-66
- Sanchez AR, Sheridan PJ, Kupp LI. Is platelet-rich plasma the perfect enhancement factor? A current review. *Int J Oral Maxillofac Implants* 2003; 18:93-103
- Albanese A, Licata ME, Polizzi B, et al. Platelet-rich plasma (PRP) in dental and oral surgery: from the wound healing to bone regeneration. *Immun Ageing* 2013; 10(1):23
- Misch CE, Wang HL, Misch CM, et al. Rationale for the application of immediate load in implant dentistry: Part I. *Implant Dent* 2004; 13:207-17
- Guess PC, Att W, Strub JR. Zirconia in fixed implant prosthodontics. *Clin Implant Dent Relat Res* 2012; 14(5):633-45
- Mombelli A, Van Oosten MA, Schurch E. The microbiota associated with successful or failing osseointegrated titanium implants. *Oral Microbiol Immunol* 1987; 2:145-51
- Apse P, Schmitt A, Lewis DW. The longitudinal effectiveness of osseointegrated dental implants. The Toronto study - Peri-implant mucosa response. *Int J Periodont Restorative Dent* 1991; 11:95-111
- Rams TE, Slots J. Comparison of two pressure sensitive periodontal probes and a manual periodontal probe in shallow and deep pockets. *Int J Periodont Restorative Dent* 1993; 13:521-9
- Misch CE. *Contemporary implant dentistry*. 3 rd ed. Amsterdam: Elsevier Publishers 2008
- Mori G, Brunetti G, Colucci S, et al. Osteoblast Apoptosis In Periodontal Disease: Role of TNF-Related Apoptosis-Inducing Ligand. *Int J Immunopathol Pharmacol*, 2009; 22(1):95-103
- Kundu R, Rathee M. Effect of Platelet-Rich-Plasma (PRP) and Implant Surface Topography on Implant Stability and Bone. *J Clin Diagn Res* 2014; 8(6):ZC26-30
- Merli M, Bernardelli F, Esposito M. Computer-guided flapless placement of immediately loaded dental implants in the edentulous maxilla: a pilot prospective case series. *Eur J Oral Implantol* 2008; 1(1):61-9
- Anand U, Mehta DS. Evaluation of immediately loaded dental implants bioactivated with platelet rich plasma placed in the mandibularposterior region: A clinico-radiographic study. *J Indian Soc Periodontol* 2012; 16(1):89-95
- Assad AS, Hassan SA, Shawky YM, et al. Clinical and radiographic evaluation of implant-retained mandibular overdentures with immediate loading. *Implant Dent* 2007; 16(2):212-3
- Ballini A, Capodiferro S, Toia M, Cantore S, Favia G, De Frenza G, Grassi FR. Evidence-based dentistry: what's new? *Int J Med Sci* 2007; 4(3):174-8